



Protective Action of an Anti-oxidant (Vitamin-C) Against Bisphenol-toxicity in *Cirrhinus mrigala* (Ham.)

Sarita Murmu^{1*}, Vinoy K. Shrivastava²

¹ Vinoba Bhawe University, S.S.L.N.T Mahila College, Department of Zoology, Dhanbad-826001, Hazaribagh India.

² Barkatullah University, Department of Bioscience, Endocrinology Lab, Bhopal-462026 India.

* Corresponding Author: Tel.: ; Fax: ;
E-mail: sunita82006@yahoo.co.in

Received 11 January 2010
Accepted 23 September 2010

Abstract

45 fishes *Cirrhinus mrigala* weighing 55 ± 10 g were divided into 3 groups of fifteen each. Group 1st received fish diet only and served as control, while group 2nd exposed with bisphenol-A (BPA) (2 mg/L) and group 3rd exposed with vitamin-C (50 mg/L) and BPA (2 mg/L) for 15, 30 and 60 days and histopathological studies were observed in their liver and kidney. Bisphenol-A showed degenerative changes in hepatic and renal cells after 15 days exposures. However, these changes were more prominent and severe in later part i.e. 30 and 60 of the experiments. The animals exposed with BPA for 30 and 60 days showed atrophied changes in uriniferous tubules and hypertrophied hepatic nuclei, necrosis in hepatocytes and interrenal cells as compared to control group. The animals exposed with vitamin-C along with BPA showed recovery in their hepatic cells, interrenal cells, and uriniferous tubules after 15, 30 and 60 days as compared to BPA groups. These observations denotes that vitamin-C i.e. antioxidant has some antidote role or protective action against bisphenol-A toxicity in *Cirrhinus mrigala*.

Keywords: Liver, kidney, histopathology, *Cirrhinus mrigala*.

Cirrhinus mrigala'da (Ham.) Bisfenol-A Toksisitesine Karşın Bir Antioksidanın (C Vitamini) Koruyucu Etkisi

Özet

Denemede 55 ± 10 g ağırlığında 45 adet *Cirrhinus mrigala* balığı her biri 15 adet olmak üzere 3 gruba ayrılmıştır. 15, 30 ve 60 gün boyunca 1. gruba yalnızca balık yemi verilmiş ve kontrol grubu olarak belirlenmiş, ikinci grup bisfenol-A'ya (BPA) (2 mg/L) ve 3. grup ise C-vitaminine (50 mg/L) ve BPA'ya (2 mg/L) maruz bırakılmıştır. Balıkların karaciğerinde ve böbreklerinde histopatolojik değişimler gözlemlenmiştir. Onbeş gün süreyle Bisfenol-A'ya maruz bırakılan balıklarda hepatic ve renal hücrelere bağlı dejeneratif değişiklikler meydana gelmiştir. Fakat bu değişiklikler daha sonraki kısımda, yani deneylerin 30 ve 60. günlerinde daha belirgin ve şiddetli hale gelmiştir. Kontrol grubuna kıyasla 30 ve 60 gün boyunca BPA'ya maruz bırakılan hayvanlarda, ürünifer tübüllerde atrofik değişiklikler ve **hipertrofi tanısı konan** hepatic nükleuslar, hepatositlerde ve interrenal hücrelerde nekroz izlenmiştir. BPA'ya maruz kalanlara kıyasla 15, 30 ve 60 gün sonra, C vitaminiyle birlikte BPA'ya maruz kalan hayvanların hepatic hücrelerinde, interrenal hücrelerinde ve ürünifer tübüllerinde iyileşme görülmüştür. C vitamininin yani antioksidanın, *Cirrhinus mrigala*'da bisfenol-A toksisitesine karşı panzehir rolü veya koruyucu tedbir dozu özelliği olduğu yapılan gözlemlerle işaret edilmiştir.

Anahtar Kelimeler: Karaciğer, böbrek, histopatoloji, *Cirrhinus mrigala*.

Introduction

Bisphenol-A (BPA) or 2,2-bis(hydroxy-phenyl)propane is the building block of polycarbonate plastics, a hard plastic used to make numerous consumer products, including most baby bottles and water bottles. Its final product includes adhesives, coatings, paints, building materials (Staples *et al.*, 1998). BPA waste may enter the environment during handling, loading and unloading, heating or releases. BPA leaches out in trace amount

from resins and polycarbonates plastics of food packages (Knaak and Sullivan, 1966; Krishnan *et al.*, 1993). BPA can enter the human body through reusable baby bottles (Biles *et al.*, 1997), food packing materials (Krishnan *et al.*, 1993), liquid of canned vegetables (Brotons *et al.*, 1995), and dental sealants (Olea *et al.*, 1996).

BPA is one of the major flame retardants and is also a known endocrine-disrupting chemical (EDC) (Meerts *et al.*, 2001). It has been known that BPA has the efficacy of the hormone estradiol in some tissues

(Dodds and Lawson, 1936), and it has recently been shown to also antagonize thyroid hormones action (Moriyama *et al.*, 2002) and antagonize androgen action (Lee *et al.*, 2003). However, BPA acts as an agonist for a mutant form of the androgen receptor found in some prostate cancers (Wetherill *et al.*, 2002). BPA has been also shown to antagonize the action of estradiol in the rat hippocampus by blocking the stimulatory effects of estradiol on synaptogenesis (MacLusky *et al.*, 2005). Besides this, it has also noticed that BPA act as a highly potent estradiol mimetic and also to disrupt the rapid actions of estradiol at very low concentration during cerebellar development via rapid nongenomic signaling system (Zsamovszky *et al.*, 2005). The evidence of both humans and animal models suggest that *in utero* exposure to an estrogenic environment increases breast cancer risk later in life depends on the timing of environmental exposure. (Hilakivi-Clarke *et al.*, 2001; Birnbaum and Fenton, 2003).

Besides this, it has well known that vitamin-C (Ascorbic acid) is a water-soluble antioxidant and its role is to neutralize free radicals by donating electrons to free radicals such as hydroxyl and superoxide radicals and quench their reactivity" (Bendich, 1990). Vitamin-C protects the DNA of the cells from the damage caused by free radicals and mutagens. It prevents harmful genetic alteration with in cells and protects lymphocytes from mutations to the chromosomes (Gaby and Singh, 1991). Besides this, vitamin-C prevents free radical damage in the lungs and may even help to protect the central nervous system from such damage (Kronhausen *et al.*, 1989). Moreover, vitamin-C also protects us by preventing the development of nitrosamines, the cancer-causing chemicals that stem from the nitrates contained in many food (Gaby and Singh, 1991). Hepatic damage induced by lead has been reported to be neutralized by a combination of ascorbic acid and thiamine (Wang *et al.*, 2007). Protective effects of vitamin-C against chlorpyrifos poisoning on haematological and biochemical changes were reported by Ambali *et al.*, 2007. In present experimental investigation has been attempt to evaluate that the protective action of antioxidant (vitamin-C) against bisphenol-A toxicity by

observing histopathological changes in liver and kidney of *Cirrhinus mrigala*.

Materials and Method

45 fishes *Cirrhinus mrigala* weighing 55 ± 10 g was acclimated in the laboratory condition prior to initiation of the experiment. The fishes were divided in three groups of fifteen each. Group 1st received fish diet only and served as control, while group 2nd exposed with Bisphenol-A (2 mg/L) and group 3rd exposed with Bisphenol-A (2 mg/L) and supplemented with vitamin-C (50 mg/L) for 15, 30 and 60 days. The relative body weight were recorded at different intervals and the significant values were calculated by Student "t" test. Fishes were sacrificed and their liver and kidney were dissected out quickly and kept in Bouin's fixative for histopathological studies. Tissues were cut at 5-6 μ thick and stained with haematoxylin and Eosin by using Ehrlich's (1986) methodology.

Results

Fishes *Cirrhinus mrigala* treated with Bisphenol-A changed the colour of the skin it becomes light brickish skin. When fishes exposed with Bisphenol-A (2 mg/L) and vitamin-C (50mg/L) showed recovery in their skin. While, the fishes exposed with Bisphenol-A; and vitamin-C along with Bisphenol-A showed insignificant increased in their body weights as compared to control (Figure 1). However, fishes exposed with Bisphenol-A showed degenerative changes in hepatic and renal cells after 15 days exposures (Figure 2a and 3a). The animals exposed with BPA for 30 and 60 days showed more atrophied changes in uriniferous tubules and hypertrophied hepatic nuclei, characterized by pycknotic nuclei in hepatic cells, necrosis in uriniferous tubules, interrenal cells as compared to control group (Figure 2d, 2f and 3c, 3f). However, these changes were more prominent in later part of the experiments. In connection to this, fishes exposed with Bisphenol-A and supplemented with vitamin-C showed recovery in their hepatic cells, uriniferous

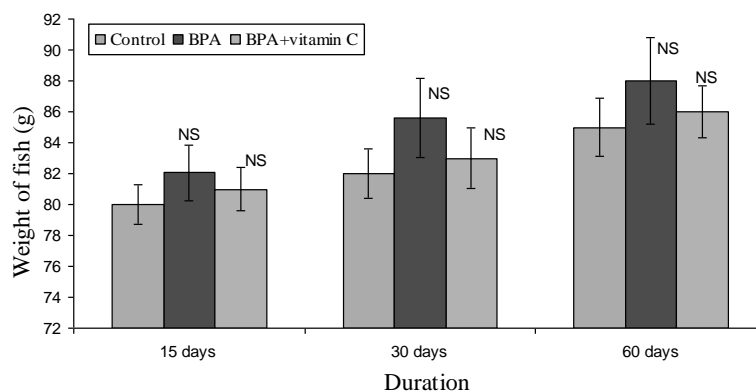


Figure 1. Body weight (g) of *Cirrhinus mrigala* after Bisphenol A and vitamin C along with Bisphenol A exposures. Values are mean \pm SEM of 5 fishes. NS= Not Significant.

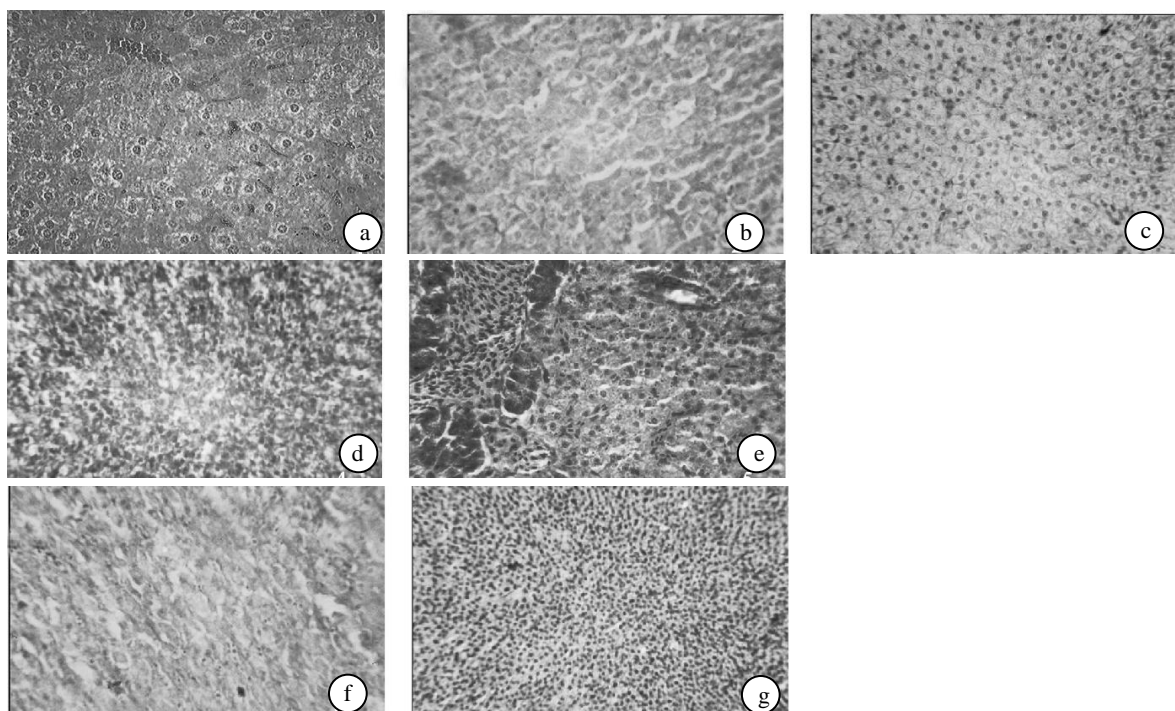


Figure 2. Liver control-(figure 2a), liver treated for 15, 30 and 60 days of BPA (2 mg/L)-(figure 2b, 2d, 2f), liver treated for 15, 30 and 60 days of vitamin-C(50 mg/L) along with BPA (2 mg/L)-(figure 2c, 2e and 2g).

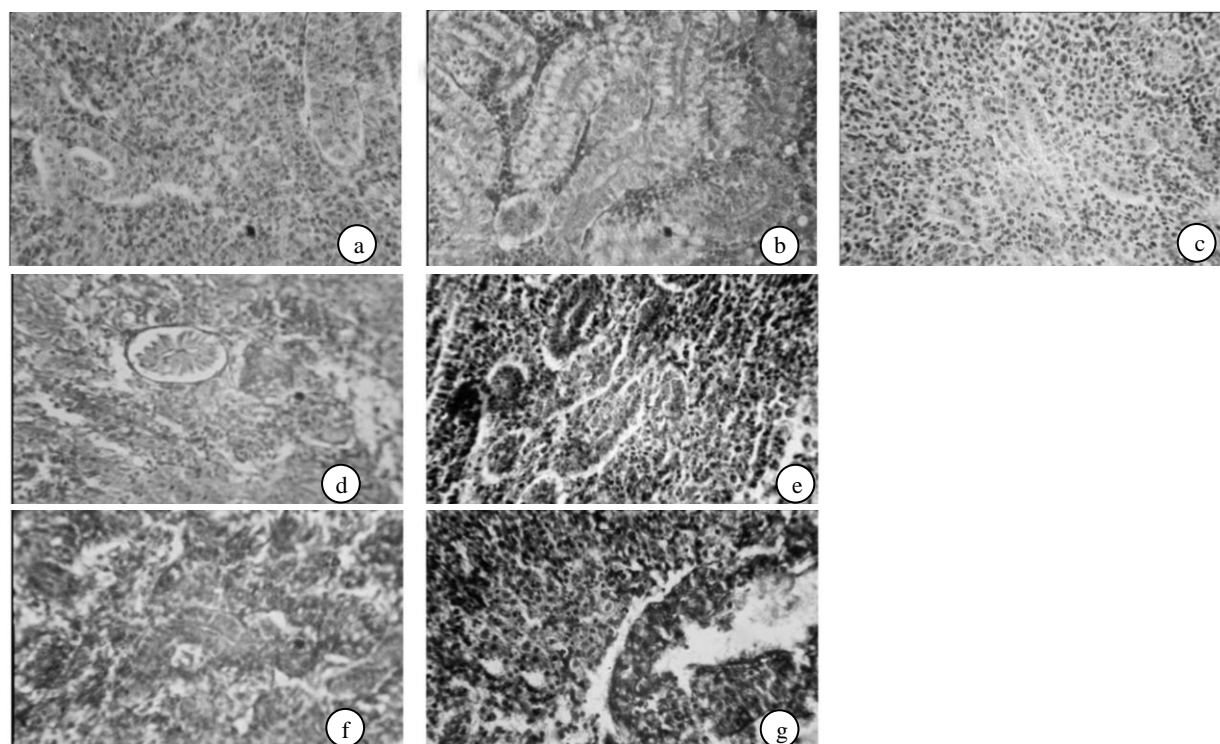


Figure 3. Kidney control-(Figure 3a), kidney treated for 15, 30 and 60 days of BPA (2 mg/L)-(Figure 3b, 3d, and 3f), kidney treated for 15, 30 and 60 days of vitamin-C(50 mg/L) along with BPA (2 mg/L)-(Figure 3c, 3e, 3g).

tubules and interrenal cells as compared to Bisphenol-A treated group (Figure 2c, 2e, 2g and 3c, 3e, 3g).

Discussion

BPA environmental oestrogenic chemicals, are glucuronidated in rat liver microsomes and,

furthermore, that the isoform UGT2B1 is responsible for their glucuronidation (Yokota *et al.*, 1999). Knaak and Sullivan (1966) reported that 28% of BPA was excreted in urine, primarily as the glucuronide. Glucuronidation is a major detoxification pathway in all vertebrates, whereas it is rare in invertebrates (Dutton, 1980). BPA has been reported to be

hydroxylated *in vivo* (Knaak and Sullivan, 1966) and to bind to DNA (Atkinson and Roy, 1995).

The liver of fish can be considered a target organ to pollutants, alterations in its structure can be significant in the evaluation of fish health (Myers *et al.*, 1998), and exhibit the effects of a variety of environmental pollutants (Hinton *et al.*, 1992). Moreover, the liver has play a major role in complex enzymatic processes of tetraiodothyronine (thyroxine)-tri-iodothyronine (T4-T3) conversion.

The fibrosis, steatosis, hyperemia and necrosis; which were formed a rectangle of hepatic tissue changes, are similar to those reported for fish caught in contaminated water or exposed ones to various chemicals in laboratory conditions (Brand *et al.*, 2001; Koehler, 2004; Olojo *et al.*, 2005; Camargo and Martinez, 2007; Wahbi and El-Greisy, 2007; Aniladevi *et al.*, 2008). Fibrosis and local blood congestions in the liver sinusoids of the flounder, *Platichthys flesus*, the ruffe, *Gymnocephalus cernua*, and the smelt, *Osmerus eperlanus*, were reported as a consequence of pollution by Peters *et al.* (1987). Radhaiah and Jayantha (1992) reported moderate cytoplasmic degeneration in hepatocytes, formation of vacuoles, rupture in blood vessels, and pyknotic nuclei in the liver of *Tilapia mossambica* exposed to fenvalerate. Tilak *et al.* (2005) observed the same changes in liver of *Catla catla* ex-posed to chlorpyrifos.

Moreover, recent studies have also shown that concentrations of 4-NP and BPA that inhibit gonadal development and reproductive function in fish can also cause damage to the kidneys (as a consequence of VTG induction) and decreased body weight and induce stressed behavior (Magliulo *et al.*, 2002) as well as result in damage to DNA in barnacles, (Atienzar *et al.*, 2002) and to the immune system in rats (Karrow *et al.*, 2004). Histopathological alterations in the kidney tissues of rats such as tissue impairment, swelling of the lining epithelium of glomeruli, injured brush border of proximal convoluted tubules, necrotic lesions of the urinary tubules and focal hemorrhage between the degenerative renal tubules have been reported by Aughey *et al.* (1984), Kjellstrom (1986), Mitsumari *et al.* (1998), Inkielewicz and Krechniak (2003). The effluent-exposed fish was detectable in many of the body tissues, including the liver (the site of its synthesis), kidney, and gonad (ovaries and testes). Several noticeable changes in histological patterns of liver were also noted. In present study; it has been observed that BPA showed degenerative changes in hepatic, interrenal cells and uriniferous tubules in 15 days exposures. Whereas, BPA after 30 and 60 days showed atrophy and necrosis of hepatic cells, interrenal cells and uriniferous tubules as compared to control. These, changes were more prominent in later part of the experiment. Exposures of Bisphenol-A and supplement of vitamin-C showed recovery in hepatic cells, interrenal cells and uriniferous tubules

as compared to Bisphenol-A group. These showed that vitamin-C denotes as antidote against Bisphenol toxicity in *Cirrhinus mrigala*.

Acknowledgement

Authors are thankful to Prof. Meenakshi Benerjee, Head Department of Biosciences, B.U. Bhopal, for providing infrastructure facilities in the Department.

References

- Ambali, S., Akanbi, D., Igbokwe, N., Shittu, M., Kawu, M. and Javo, J. 2007. Evaluation of subchronic chlorpyrifos poisoning on hematological and serum biochemical changes in mice and protective effects of vitamin-C. *J. of Toxicological Science*, 32(1): 111-20.
- Aniladevi Kunjamma, K.P., Philip, B., Smitha, V., Bhanu, S.V. and Jose, J. 2008. Histopathological effects on *Oreochromis mossambicus* (Tilapia) exposed to chlorpyrifos. *Journal of Environmental Research and Developmental*, 2(4): 553-559.
- Atienzar, F.A., Billingham, Z. and Depledge, M.H. 2002. 4-n-Nonylphenol and 17-beta estradiol may induce common DNA effects in developing barnacle larvae. *Environmental Pollution*, 120(3):735-738.
- Atkinson, A. and Roy, D. 1995. *In vitro* conversion of environmental estrogenic chemical bisphenol-A to DNA binding metabolite(s). *Biochemical and Biophysical Research Commun.*, 210: 424-433.
- Aughey, E., Feli, G.S., Scott, R. and Black, M. 1984. Histopathology of early effects of oral cadmium in the rat kidney, *Env. and Health Perspectives*, 54: 153-161.
- Bendich, A. 1990. Antioxidant micronutrients and immune responses. In: A. Bendich, and R.K. Chandra (Eds.), *Micronutrients and immune functions*. N.Y. Academy of Sciences, New York, 175 pp.
- Biles, J.E., McNeal, T.P., Begley, T.H. and Hillifield, H.C. 1997. Determination of bisphenol-A in reusable polycarbonate food-contact plastics and migration to food-simulating liquids. *Journal of Agriculture and Food Chemistry*, 45: 3541-3544.
- Birnbaum, L.S. and Fenton, S.E. 2003. Cancer and developmental exposure to endocrine disruptors. *Environmental Health Perspectives*, 111: 389-394.
- Brand, D.G., Fink, R., Bengyfield, W., Birtwell, I.K. and McAllister, C.D. 2001. Salt water-acclimated pink salmon fry (*Oncorhynchus gorbuscha*) develop stress-related visceral lesions after 10-day exposure to sublethal concentrations of the water-soluble fraction of North Slope crude oil. *Toxicologic Pathology*, 29(5): 574-584.
- Brotons, J.A., Olea-Serrano, M.F., Villalobos, M., Pedraza, V. and Olea, N. 1995. Xenoestrogens released from lacquer coatings in food cans. *Environmental Health Perspectives*, 103: 753-758.
- Camargo, M.M.P. and Martinez, C.B.R. 2007. Histopathology of gills, kidney and liver of a neotropical fish caged in an urban stream. *Neotropical Ichthyology*, 5(3): 327-336.
- Dodds, E.C. and Lawson, W. 1936. Synthetic oestrogenic agents without the phenanthrene nucleus. *Nature*, 137: 996.
- Dutton, G.J. 1980. Glucuronidation of Drugs and Other

- Compounds, CRC Press, Boca Raton: 99-180.
- Ehrlich, P. 1986. Fragkaster Zeitshft Fur Wissenschaftliche Mikroskopie and Fur Mikroskopische Technik, 3: 150.
- Gaby, S.K. and Singh, V.N. 1991. "Vitamin-C"-Vitamin intake and health: A scientific review, In: S.K. Gaby, A. Bendich, V.N. Singh and L. Machlin (Eds.), Marcel Dekker, New York: 320-325.
- Hilakivi-Clarke, L., Cho, E., deAssis, S., Olivo, S., Ealley, E., Bouker, K.B., Welch, J.N., Khan, G., Clarke, R. and Cabanes, A. 2001. Maternal and prepubertal diet, mammary development and breast cancer risk. *Journal of Nutrition*, 131: 154-157.
- Hinton, D.E., Baumann, P.C., Gardner, G.R., Hawkins, W.E., Hendricks, J.D., Murchelano, R.A. and Okihiro, M.S. 1992. Histopathologic biomarkers. In: Huggett RJ, Kimerle RA, Mehrle JR, Bergman HL, Editors, Bio- markers: Biochemical, Physiological and Histological Markers of Anthropogenic Stress, Lewis Publishers, Boca Raton: 155-209.
- Inkiewicz, I. and Krechniak, J. 2003. Fluoride content in soft tissues and urine of rats exposed to sodium fluoride in drinking water, fluoride, *Research Report*, 36(4): 263-266.
- Karrow, N.A., Guo, T.L., Delclos, K.B., Newbold, R.R., Weis, C. and Germolec, D.R. 2004. Nonylphenol alters the activity of splenic NK cells and the numbers of leukocyte subpopulations in Sprague-Dawley rats: a two-generation feeding study. *Toxicology*, 196(3): 237-245.
- Kjellstrom, T. 1986. Renal effects in cadmium and health: In: L. Friberg, C.G. Elinder, T. Kjellstrom, and G.F. Norgderg (Eds.), *A Toxicology and Epidemiological Appraisal*, CRC Press, Boca Raton: 21-109
- Knaak, J.B. and Sullivan, L.J. 1966. Metabolism of bisphenol A in the rat. *Toxicology and Applied Pharmacology*, 8:175-184.
- Koehler, A. 2004. The gender-specific risk to liver toxicity and cancer of flounder (*Platichthys flesus* L.) at the German Wadden Sea coast. *Aquatic Toxicological*, 70(4): 257-276.
- Krishnan, A.V., Stathis, P., Permeth, S.F., Tokes, L. and Feldman, D. 1993. Bisphenol-A: an estrogenic substance is released from polycarbonate flasks during autoclaving. *Endocrinology*, 132: 2279-2286.
- Kronhausen, E., Kronhausen, P. and Demopoulos, H.B. 1989. *Formula for Life*, William Morrow Co., New York: 95-103.
- Lee, H.J., Chattopadhyay, S., Gong, E.Y., Ahn, R.S. and Lee, K. 2003. Antiandrogenic effects of bisphenol-A and nonylphenol on the function of androgen receptor. *Toxicological Sciences*, 75-40.
- MacLusky, N.J., Hajszan, T. and Leranthy, C. 2005. The environmental estrogen bisphenol-A inhibits estrogen-induced hippocampal synaptogenesis. *Environmental Health Perspective*, 113: 675-679.
- Magliulo, L., Schreiberman, M.P., Cepriano, J. and Ling, J. 2002. Endocrine disruption caused by two common pollutants at "acceptable" concentrations. *Neurotoxicology and Teratology*, 24(1):71-79.
- Meerts, I.A., Letcher, R.J., Hoving, S., Marsh, G., Bergman, A., Lemmen, J.G., van der Burg, B. and Brouwer, A. 2001. *In vitro* estrogenicity of polybrominated diphenyl ethers, hydroxylated PBDEs and polybrominated bisphenol-A compounds. *Environmental Health Perspectives*, 109: 399-409.
- Mitsumari, K., Shibutani, S., Sato, S., Ondoera, H., Hacagawa, J., Hayashi, Y. and Ando, M. 1998. Relationship between the development of hepatorenal toxicity and cadmium accumulation in rats. *Archives of Toxicology*, 72: 545-552.
- Moriyama, K., Tagami, T., Akamizu, T., Usui, T., Saljo, M., Kanamoto, N., Hataya, Y., Shimatsu, A., Kuzuya, H. and Nakao, K. 2002. Thyroid hormone action is disrupted by bisphenol-A as an antagonist. *Journal of Clinical Endocrin. and Metabolism*, 87: 5185-5190.
- Myers, M.S., Johnson, L.L., Olson, O.P., Sther, C.M., Horness, B.H., Collier, T.K. and McCain, B.B. 1998. Toxicopathic hepatic lesions as biomarkers of chemical contaminant exposure and effects in marine bottomfish species from the Northeast Pacific Coast. USA. *Marine Pollution Bulletin*, 37: 92-113.
- Olea, N., Pulgar, R., Perez, P., Olea-Serrano, F., Rivas, A., Norvillo-Fertell, A., Pedraza, V. Soto, A.M. and Sonnenschein, C. 1996. Estrogenicity of resin-based composites and sealants used in dentistry. *Environmental Health Perspectives* 104: 298-305.
- Olojo, E.A.A., Olurin, K.B., Mbaka, G. and Oluwemimo, A.D. 2005. Histopathology of the gill and liver tissues of the African catfish *Clarias gariepinus* exposed to lead. *African Journal of Biotechnology*, 4(1): 117-122.
- Peters, N., Köhler, A. and Kranz, H. 1987. Liver pathology in fishes from the lower Elbe as a consequence of pollution. *Diseases of Aquatic Organisms*, 2: 87-97.
- Radhaiah, V. and Jayantha, Rao. K. 1992. Fenvalerate toxicity to the liver in a freshwater teleost, *Tilapia mossambica* (Peters). *Comparative Physiology and Ecology*, 17(2): 48-53.
- Staples, C.A., Dorns, P.B., Klecka, G.M., O'Block, S.T. and Harris, L.R. 1998. A review of the environmental fate, effects and exposures of bisphenol-A. *Chemosphere*, 36: 2149-2173.
- Tilak, K.S., Koteswara, R. and Veeraiiah, K. 2005. Effects of chlorpyrifos on histopathology of the fish *Catla catla*. *Journal of Ecotoxicological & Environmental Monitoring*, 15(2): 127-140.
- Wahbi, O.M. and El-Greisy, Z.A. 2007. Comparative impact of different waste sources on the reproductive parameters and histology of gonads, liver and pituitary gland of *Siganus rivaltus*. *Journal Applied Sciences Research*, 3(3): 236-244.
- Wang, C., Liang, J., Zhang, C., Bi, Y., Shi, X. and Shi, Q. 2007. Effects of Ascorbic acid and thiamine supplementation at different concentrations on lead toxicity in liver. *Annals Occupational Hygiene*, 51(6): 563-569.
- Wetherill, Y.B., Petra, C.E., Monk, K.R., Puga, A. and Knudsen, K.E. 2002. The xenoestrogen bisphenol-A induces inappropriate androgen receptor activation and mitogenesis. In prostate adenocarcinoma cells. *Molecular Cancer Therapy*, 7: 515-524.
- Yokota, H., Iwano, H., Endo, M., Kobayashi, T., Inone, H., Ikushiro, S.I. and Yuasa, A. 1999. Glucuronidation of the environmental oestrogen bisphenol-A by an isoform of UDP-glucuronosyltransferase, UGT2B1, in the rat liver. *Biochemical Journal*, 340: 405-409.
- Zsarnovszky, A., Le, H.H., Wang, H.S. and Belcher, S.M. 2005. Ontogeny of rapid estrogen-mediated extracellular signal-regulated kinase signaling in the rat cerebellar cortex: potent nongenomic agonist and endocrine disrupting activity of the xenoestrogen bisphenol-A. *Endocrinology*, 146: 5388-5396.