



Occurrence of Intersex in Grey Mullet, *Mugil cephalus* L. from Kovalam Coast, Tamil Nadu

Krishnamoorthy Dhanasekar¹, Narasimman Selvakumar¹, Natesan Munuswamy^{1,*}

¹ University of Madras, Department of Zoology, Unit of Aquaculture and Cryobiology, Guindy Campus, Chennai- 600 025, Tamil Nadu, India.

* Corresponding Author: Tel.: +91.44 2539 9422;
E-mail: munuswamynm@yahoo.com

Received 21 February 2017
Accepted 22 August 2017

Abstract

The present study documents the occurrence of an intersex condition in a natural population of mullet *Mugil cephalus* L. On closure examination of the dissected fish, 11 females and 7 males were recorded. Histological observations through the testes indicated that one of the male fish showed different developmental stages of oocytes in between the seminiferous tubules. Interestingly, the condition reported here did not show any internal bilateral division of the reproductive system into male and female components. But it had shown the occurrence of oocytes and spermatozoa throughout the entire region of the testis of a functional male. The observation of intersex testis or testicular oocytes (TO) is of first report from the east coast of India. The fish being catadromous, this condition may be related to possible accumulation of chemical contaminants in the habitat water.

Keywords: Chemical contaminants, intersex, *Mugil cephalus*, mullet and testicular oocytes.

Introduction

Intersex is regarded as the presence of male and female gonadal tissue simultaneously in an individual of a gonochoristic form (fixed-sex) (Tyler & Jobling, 2008). The most frequently reported manifestation of intersex is the presence of single or multiple oocytes within the testes of sub-adult or adult males. However, several other manifestations, such as the presence of testicular tissue within ovaries or the feminization of male gonadal ducts, have also been documented (Nolan, Jobling, Brighty, Sumpter, & Tyler, 2001). In terms of aquatic contaminants, intersex presents can vary according to the exposure and it could be a feminization process (i.e. the presence of oocytes in the testes (Nolan *et al.*, 2001) or a masculinization process (i.e. the presence of spermatozoa with previtellogenic oocytes) (Hinck *et al.*, 2007).

Intersex also referred to as ovotestis, testis-ova or testicular oocytes (TO) (Hecker *et al.*, 2006). It has received considerable attention recently in both the public and scientific studies. While, intersex is most commonly described as the presence of female germ cell oocytes within a male gonad predominantly (Nolan *et al.*, 2001). The abnormality of oocytes was observed in the male gonad and referred to as

testicular oocytes (TO) in small mouth bass *Micropterus dolomieu*. Occasionally, these abnormalities are visible macroscopically but most often the gonad must be examined microscopically for clear detection (Blazer *et al.*, 2007).

In fishes, those are normally gonochoristic, the presence of TO have been used as an indicator of exposure to estrogenic compounds and reported in a variety of wild fish species from various geographic areas (Blazer *et al.*, 2007). Testicular oocytes are generally induced experimentally by exposure of fish species to estradiol, including medaka *Oryzias latipes* (Koger, Teh, & Hinton, 2000; Hirai *et al.*, 2006), rainbow trout *Oncorhynchus mykiss* (Krisfalusi & Nagler, 2000), zebrafish *Danio rerio* (Brion *et al.*, 2004), and the estuarine fish, Javanese ricefish *Oryzias javanicus* (Imai, Koyama, & Fujii, 2005).

In general, endocrine-disrupting compounds (EDCs) have the potential to perturb sensitive hormone pathways that regulate reproductive functions. In fish, this may result in decreased fertility and egg production in females, or lead to reduced gonad size or feminization of genetic male fish and also that male fish exposed to estrogenic compounds show induced production of vitellogenin, but the organismal significance of elevated vitellogenin levels has only been, for the most part, speculative (Arcand-

Hoy & Benson, 1998). Furthermore, prevalence of intersex in some estuarine and marine species such as the European flounder *Platichthys flesus* are studied (Allen *et al.*, 1999). The effects of EDCs extend beyond Inland river systems to coastal waters are well screened in Japanese flounder *Pleuronectes yokohamae* (Hashimoto *et al.*, 2000).

Intersexuality, which occurs frequently in fishes was discussed in detail described as previously (Atz, 1964) and both normal and abnormal specimens (Dawson, 1971). Explained the importance of characterizing intersex condition in aquatic organisms in order to establish baseline prevalence and factors promoting the development of intersex (Bahamonde, Munkittrick, & Martyniuk, 2013). The intersex condition was first detected in wild populations of roach, but since then, several studies have demonstrated by the appearance of intersex in several fish species, related to EDCs exposure (Bahamonde *et al.*, 2013) including thick lip grey mullets (*Chelon labrosus*) from the Biosphere Reserve of Urdaibai in the Basque Coast (Puy-Azurmendi *et al.*, 2013). The thicklip grey mullet is a coastal fish of the family Mugilidae, which included around 80 species widely distributed all around the world and occupying numerous habitats (Whitfield, Elliott, Basset, Blaber, & West, 2012). All grey mullets are abundant in estuaries and inshore waters, where they spend most of their life, but they spawn in marine waters (Luther, 1977). The reproductive cycle of a few grey mullet species in some of the estuaries and lagoons has been analyzed (Brusle, 1981; Hotos, Avramidou, & Ondrias, 2000).

Unfortunately, after extensive land reclamation of lagoons and brackish water lakes together with the constant pollution from agriculture and upstream industries and high fishing pressure, the status of mugilids is now fragile. At least one species, flathead grey mullet, *Mugil cephalus* L. 1758, is becoming endangered and rare (Glamuzina & Bartulovic, 2010). Mulletts have been proposed as sentinel organisms of environmental pollution using both wild and caged individuals (Whitfield *et al.*, 2012; Diaz de Cerio, Rojo-Bartolome, Bizarro, Ortiz-Zarragoitia, & Cancio, 2012; Waltham, Teasdale, & Connolly, 2013) and are sensitive organisms to EDCs (Puy-Azurmendi *et al.*, 2013; Ferreira, Antunes, Gil, Vale, & Reis-Henriques, 2004; Aoki *et al.*, 2010). Therefore, the present study was aimed to document the occurrence of intersex, if any, in the grey mullet, *Mugil cephalus* population fished off from Kovalam coast, East coast of India.

Materials and Methods

Fish sampling

Samples of mullet (totally 18) were obtained from the Kovalam landing centre (Lat. 12°46'; Long. 80°18'). Immediately after landing the fishes were

iced instantly, brought to the laboratory. Measurements like total length (TL, mm) and total weight (TW, g) of all the fishes were made. For gonadosomatic index (GSI) analysis, the testis and ovaries of each fish were dissected out from the body cavity and weighed using an electronic balance. The GSI for each male was measured as described by others (McDonough, Roumillat, & Wenner, 2003).

Histology

For histological studies, a piece of gonadal tissue was fixed in 10% neutral buffered formaldehyde solution (pH 7.0) and processed as per the standard procedure. The sections of 6-7 μ m thickness were taken and stained using hematoxylin and eosin. Photomicrographs were taken at various magnifications using Leica microscope (Germany).

Results

A total number of 18 fishes belonging to mullet, *Mugil cephalus* were obtained from a natural population off Kovalam coast, Chennai. To understand the sex of the fishes, a gentle pressure was applied at the abdominal region and based on the gamete oozing out; they were tentatively identified as 11 females and 7 males. On closure examination of the dissected fish, the sex of the fishes was further confirmed by testis and ovary which occupied most of the body cavity and appeared distinctly from other individual organs. The testes are seen as white, paired and elongated structure covered by thin peritoneal layer (Figure 1a). Testes measured about 75±27.4 mm in length and the right one was usually larger than the left (Figure 1b). Length wise male fishes measured around 387±79 mm and female around 410±17 mm. Female fishes weighed to 810±86 g. whereas, male fish weighed to 780±20 g. With reference to GSI, male fish registered a value of 1.77±0.82 while the female had 2.02±0.21. The morphometric observations clearly indicated that the fishes were sexually mature. Further histological studies performed on gonadal tissue of the fish showed a normal development of gametes. Interestingly one of the male fish showed the presence of oocytes in the testicular region. On examination, the oozing out white milt with high viscosity showed the presence of mature sperm with high motility but there were no remnants of oocytes in the milt.

Histological evaluation of the testes showed the normal lobular structure of seminiferous tubules and germ cells of all stages of spermatogenesis (Spermatogonia, Spermatocytes, Spermatid and Spermatozoa). Highly condensed residual sperms were observed and the presence of mature spermatozoa in the seminiferous tubules indicated a normal process of spermatogenesis in the intersex male. Interestingly, in the intersex fish, the gonad did not show any external or internal bilateral division of

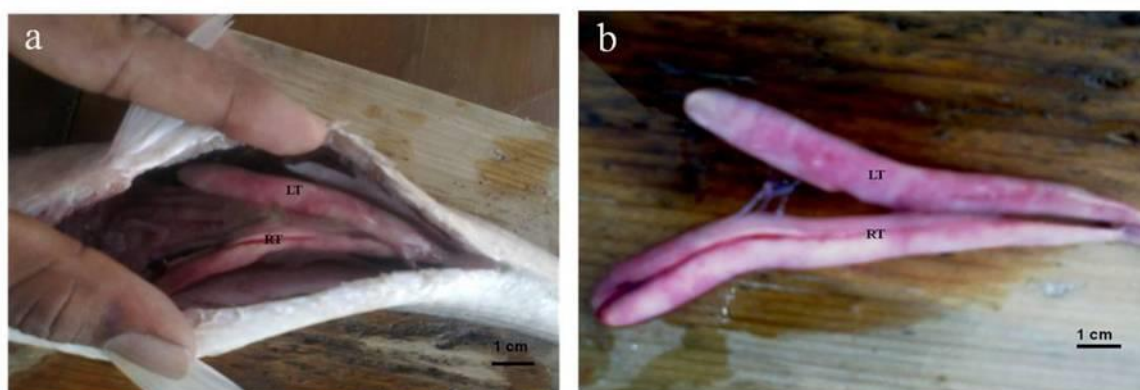


Figure 1. a) Dissected fish of mullet (intersex) showing a pair of testis. **b)** Enlarged view, showing gross morphology of the testis.

the reproductive system into male and female components. But it showed the occurrence of both oocytes and spermatozoa throughout the entire region of the testis. With reference the occurrence of oocytes, as many as five stages were evident in the testicular region of the intersex male. These stages are described as perinuclear stage with numerous nucleoli and these nucleoli are arranged in the periphery of the nucleus (Figure 2a). In vacuolization stage, oocytes are surrounded by vitelline membrane (Stage 2) (Figure 2b). The yolk granular oocytes (Stage 3) with yolk globules in the ooplasm with yolk vesicles are seen at the outer border of the cytoplasm (Figure 2c). Stage 4, denoted as germinal vesicle migration stage of oocytes wherein migrating nucleus towards the periphery of the oocytes occurred with nucleoli (Figure 2d). Due to the absence of oviduct, oocytes failed to ovulate. This resulted in the formation of atretic oocytes (stage 5). These oocytes had lost their shape, vitelline membrane thickness and their nuclei dissolved (Figure 2e).

Discussion

Many teleosts are gonochorists, where in individuals develop either as males or females, and remain in the same condition (sex) throughout their life span. It is important to note that the final sexual status of maturity achieved in fish may not reflect the initial gonadal developmental pathway taken. For example, gonochorists may develop directly as male or female, or they may develop with gonads that are initially hermaphroditic but that subsequently resolve into only functional ovaries or testis. With respect to mechanisms of sex determination, this latter group may be more like functional hermaphrodites than direct gonochorists, having simply lost the ability to retain both gonadal tissue types through to sexual maturity (Devlin & Nagahama, 2002). In the present study, the occurrence of intersex was observed in the wild population of mullet during their peak spawning season.

The intersex condition is well described in various studies from the gonads of several wild gonochoristic teleost fish species inhabiting riverine and estuarine habitats. In many cases, the condition

has been linked to the ambient presence of chemicals known to disrupt normal hormonal functioning of the host (Stentiford & Feist, 2005). Similar reports in other mullet species such as flathead grey mullet, as much as 21% of intersex was registered from the polluted environment Bay of Biscay and Northern Spain (Puy-Azurmendi *et al.*, 2013; Bizarroa *et al.*, 2014). Similarly, *Cyprinus carpio* is found to possess developed oviducts and poorly developed testes when exposed to exogenous oestrogens during sexual differentiation (Gimeno, Gerritsen, Bowmer, & Komen, 1996). Cases of intersex in wild fish, ranges from mild to severe (Allen *et al.*, 1999), viviparous blenny (Matthiessen *et al.*, 2002), roach (Jafri & Ensor, 1979; Purdom *et al.*, 1994; Jobling, Nolan, Tyler, Brighty, & Sumpter, 1998), coregonids (Mikaelian, De Lafontaine, Harshbarger, Lee, & Martineau, 2002) and grayling (*Thymallus thymallus*) (Blachuta, Witkowski, & Kokurewicz, 1991). Testicular oocytes were more apparent in the central region of the smallmouth bass testes, similar to that described for Japanese medaka exposed to 17 β – estradiol (Hirai *et al.*, 2006). Similarly, in the present study TO was noticed in the testis with different stages of oocytes surrounded by seminiferous tubules.

Furthermore, prevalence of intersex in wild fishes has primarily been associated with exposure to human wastewater effluent (Purdom *et al.*, 1994; Jobling *et al.*, 1998). Estrogens found in these effluents include estrone, 17 β -estradiol, and the synthetic estrogen 17 α -ethinylestradiol used in both control and hormone replacement medications (Desbrow, Routledge, Brighty, Sumpter, & Waldock, 1998). Agricultural runoff has also been associated with endocrine disruption or reproductive abnormalities due to the presence of natural and synthetic hormones, pesticides, and herbicides (Zhan *et al.*, 2000; Hanselman, Graetz, & Wilkie, 2003; Kiparissis, Balch, Metcalfe, & Metcalfe, 2003; Kojima, Katsura, Takeuchi, Niiyama, & Kobayashi, 2004; Orlando *et al.*, 2004). However, as the reports of this condition is predominantly rare in offshore species, the present report attains more importance because of TO and intersex condition is observed in mullet from Kovalam coast. In many intersex fish species, oocytes are found in the testis, e.g., in the

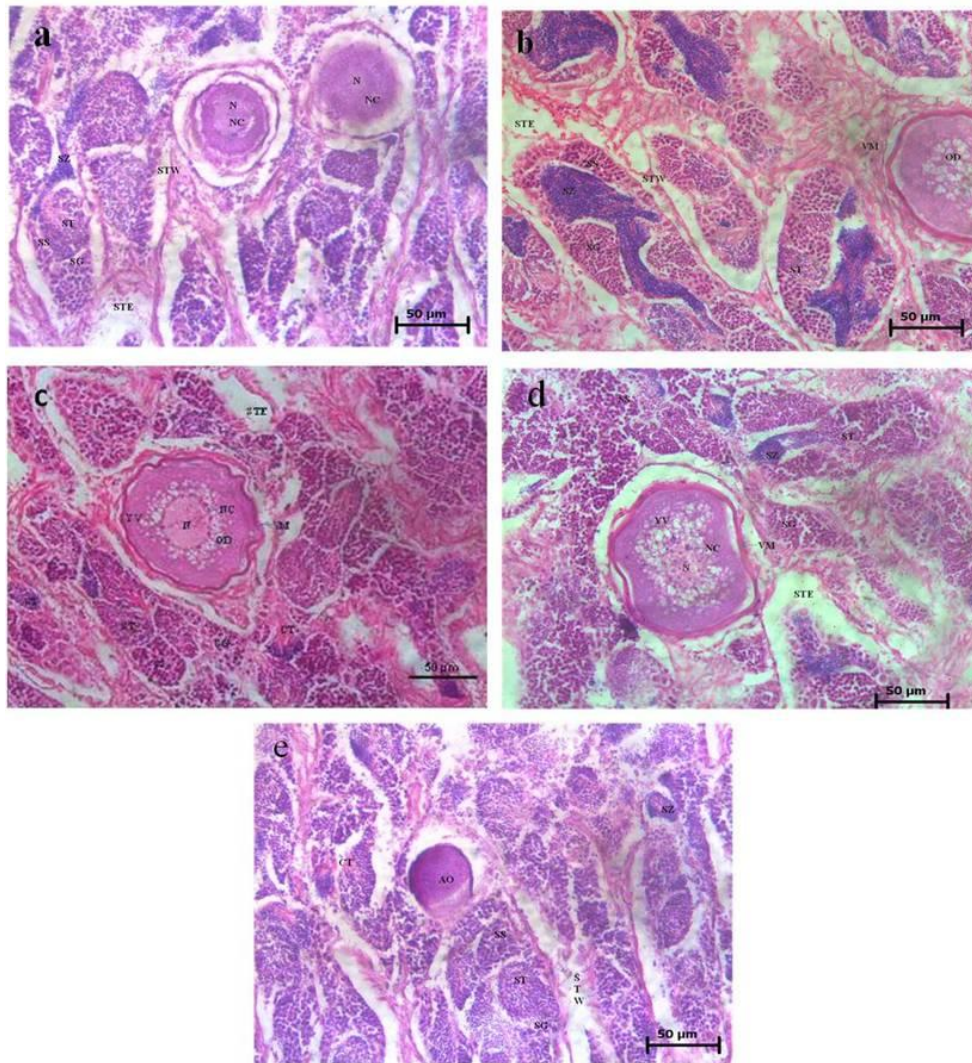


Figure 2. Photomicrographs of section through testis of intersex fish showing different maturity stages of sperm along with oocytes at different stages of maturation i.e. (a) Early perinucleolus stage of oocyte, (b) Vaculization stage of oocyte, (c) Yolk granule stage of oocyte, (d) Germinal vesical migration stage of oocyte, (e) Atretic oocytes (For details refer text). Spermatogonia(SG); Spermatocytes (SS); Spermatid (ST); Spermatozoa (SZ); Seminiferous Tubule Empty or looser (STE); Seminiferous Tubule Wall (STW); Vitelline membrane (VM); Young oocytes (YO); Yolk vesicle (YV); Nucleoli (NC); Nucleus (N); Oil droplets (OD); Atretic Oocyte (AO).

catfish *Mystus vittatus* (Srivastava & Sathyanesan, 1971), the coregonin *Coregonus lavaretus* (Scott, 1975) and in some Cichlid species (Pseudotropheus and Labeotropheus) (Peters, 1975). The present study thus reports testicular intersexuality, characterized by the presence of oocytes in the functional testes of *Mugil cephalus* as reported in some serranids (Van Oordt, 1933; Smith, 1971). Extensive review of the literature on intersexuality in bony fishes has been documented (Hashimoto *et al.*, 2000). The testicular oocytes stop growing when they have reached a certain size, e.g., 0.2 mm in cichlids (Van Oordt, 1933). In agreement with the present findings the oocytes mature upto atretic oocytes.

The testicular oocytes thus never reached vitellogenic stage and remain "blocked" in the previtellogenic stage. Later they become atrophic as ruptured (Brusle & Brusle, 1975). Tancioni *et al.*

(2014) reported that thinlip grey mullet, the intersex gonads consisted of testis-ova gonads, characterized by the presence of oocytes in testis with previtellogenic oocytes surrounded by the testis tissue. In the present study, the absence of oviduct to release the egg from the TO become atretic. However, various stage of oogenesis such as previtellogenic, vacuolization, yolk granular, germinal vesicle migration and atretic oocytes were observed the intersex in grey mullet, *Mugil cephalus*.

Conclusion

This study clearly emphasis the occurrence of intersex condition in *Mugil cephalus* as evidenced with histological observation of male gonads and may be attributed to possible endocrine disruptors.

Thereby, the occurrence of intersex, may represent a threat for conservation of mullet stocks and a possible limit for the culture practices in future.

Acknowledgements

The authors are thankful to Prof. T. J. Pandian, FNA, Emeritus Professor, for his critical review of the manuscript. Financial Assistance as UGC-BSR fellowship from University Grants Commission (UGC), Government of India, New Delhi to (K D) is gratefully acknowledged.

References

- Allen, Y., Matthiessen, P., Scott, A.P., Haworth, S., Feist, S., & Thain, J.E. (1999). The extent of oestrogenic contamination in the UK estuarine and marine environments—further surveys of flounder. *Science of the Total Environment*, 233(1), 5-20. [https://doi.org/10.1016/S0048-9697\(99\)00175-8](https://doi.org/10.1016/S0048-9697(99)00175-8)
- Aoki, J.Y., Nagae, M., Takao, Y., Hara, A., Lee, Y.D., Yeo, I.K., ... & Soyano, K. (2010). Survey of contamination of estrogenic chemicals in Japanese and Korean coastal waters using the wild grey mullet (*Mugil cephalus*). *Science of the Total Environment*, 408(3), 660-665. <https://doi.org/10.1016/j.scitotenv.2009.08.009>
- Arcand-Hoy, L.D., & Benson, W.H. (1998). Fish reproduction: an ecologically relevant indicator of endocrine disruption. *Environmental toxicology and chemistry*, 17(1), 49-57. <http://dx.doi.org/10.1002/etc.5620170108>
- Atz, J.W. (1964). Intersexuality in fishes. In C.N. Armstrong & A.J. Marshall (Eds.), *Intersexuality in Vertebrates including Man*, (pp. 145–232). Academic Press Inc., 479 pp.
- Bahamonde, P.A., Munkittrick, K.R., & Martyniuk, C.J. (2013). Intersex in teleost fish: are we distinguishing endocrine disruption from natural phenomena? *General and comparative endocrinology*, 192, 25-35. <https://doi.org/10.1016/j.ygcen.2013.04.005>
- Bizarro, C., Ros, O., Vallejo, A., Prieto, A., Etxebarria, N., Cajaraville, M.P., & Ortiz-Zarragoitia, M. (2014). Intersex condition and molecular markers of endocrine disruption in relation with burdens of emerging pollutants in thicklip grey mullets (*Chelon labrosus*) from Basque estuaries (South-East Bay of Biscay). *Marine environmental research*, 96, 19-28. <https://doi.org/10.1016/j.marenvres.2013.10.009>
- Blachuta, J., Witkowski, A., & Kokurewicz, B. (1991). An hermaphrodite grayling, *Thymallus thymallus* (L.), from the Nysa Klodzka river (Lower Silesia, Poland). *Journal of fish biology*, 38(6), 955-957. <http://dx.doi.org/10.1111/j.1095-8649.1991.tb03635.x>
- Blazer, V.S., Iwanowicz, L.R., Iwanowicz, D.D., Smith, D.R., Young, J.A., Hedrick, J.D., ... & Reeser, S.J. (2007). Intersex (testicular oocytes) in smallmouth bass from the Potomac River and selected nearby drainages. *Journal of Aquatic Animal Health*, 19(4), 242-253. <http://dx.doi.org/10.1577/H07-031.1>
- Brion, F., Tyler, C.R., Palazzi, X., Laillet, B., Porcher, J.M., Garric, J., & Flammarion, P. (2004). Impacts of 17 β -estradiol, including environmentally relevant concentrations, on reproduction after exposure during embryo-larval-, juvenile-and adult-life stages in zebrafish (*Danio rerio*). *Aquatic Toxicology*, 68(3), 193-217. <https://doi.org/10.1016/j.aquatox.2004.01.022>
- Bruslé, J. (1981). Sexuality and biology of reproduction of grey mullets. In O.H. Oren (Ed.), *Aquaculture of Grey Mulletts* (pp. 94-154). Cambridge, Cambridge University Press, 507 pp.
- Bruslé, J., & Bruslé, S. (1975). Ovarian and testicular intersexuality in two protogynous mediterranean groupers, *Epinephelus aeneus* and *Epinephelus guaza*. In R. Rudolf (Ed.), *Intersexuality in the animal kingdom*, (pp. 222-227). Springer-Verlag, Berlin, Heidelberg, New York, 449 pp. https://doi.org/10.1007/978-3-642-66069-6_21
- Dawson, C.E. (1971). A bibliography of anomalies of fishes, supplement 2. *Gulf and Caribbean Research*, 3(2), 215-239. <https://doi.org/10.18785/gr.0302.05>
- Desbrow, C.E.J.R., Routledge, E.J., Brighty, G.C., Sumpter, J.P., & Waldock, M. (1998). Identification of estrogenic chemicals in STW effluent. 1. Chemical fractionation and in vitro biological screening. *Environmental science & technology*, 32(11), 1549-1558. <https://doi.org/10.1021/es9707973>
- Devlin, R.H., & Nagahama, Y. (2002). Sex determination and sex differentiation in fish: an overview of genetic, physiological, and environmental influences. *Aquaculture*, 208(3), 191-364. [https://doi.org/10.1016/S0044-8486\(02\)00057-1](https://doi.org/10.1016/S0044-8486(02)00057-1)
- Diaz de Cerio, O., Rojo-Bartolomé, I., Bizarro, C., Ortiz-Zarragoitia, M., & Cancio, I. (2012). 5S rRNA and accompanying proteins in gonads: powerful markers to identify sex and reproductive endocrine disruption in fish. *Environmental science & technology*, 46(14), 7763-7771. <https://doi.org/10.1021/es301132b>
- Ferreira, M., Antunes, P., Gil, O., Vale, C., & Reis-Henriques, M.A. (2004). Organochlorine contaminants in flounder (*Platichthys flesus*) and mullet (*Mugil cephalus*) from Douro estuary, and their use as sentinel species for environmental monitoring. *Aquatic toxicology*, 69(4), 347-357. <https://doi.org/10.1016/j.aquatox.2004.06.005>
- Gimeno, S., Gerritsen, A., Bowmer, T., & Komen, H. (1996). Feminization of male carp. *Nature*, 384(6606), 221. <https://doi.org/10.1038/384221a0>
- Glamuzina, B., & Bartulovic, V. (2010) Grey mullets of Neretva River Delta: biology and economy. In B. Glamuzina & J. Dulcic (Eds.), *Proceedings: Fishes and Fishery of Neretva* (pp. 92- 114.). Dubrovnik: University of Dubrovnik.
- Hanselman, T.A., Graetz, D.A., & Wilkie, A.C. (2003). Manure-borne estrogens as potential environmental contaminants: a review. *Environmental science & technology*, 37(24), 5471-5478. <https://doi.org/10.1021/es034410+>
- Hashimoto, S., Bessho, H., Hara, A., Nakamura, M., Iguchi, T., & Fujita, K. (2000). Elevated serum vitellogenin levels and gonadal abnormalities in wild male flounder (*Pleuronectes yokohamae*) from Tokyo Bay, Japan. *Marine environmental research*, 49(1), 37-53. [https://doi.org/10.1016/S0141-1136\(99\)00047-1](https://doi.org/10.1016/S0141-1136(99)00047-1)
- Hecker, M., Murphy, M.B., Coady, K.K., Villeneuve, D.L., Jones, P.D., Carr, J.A., ... & Du Preez, L. (2006). Terminology of gonadal anomalies in fish and amphibians resulting from chemical exposures. In G.W. Ware (Ed.), *Reviews of environmental contamination and toxicology* (pp. 103-131), 187, Springer-Verlag New York, 261 pp.

- Hinck, J.E., Blazer, V.S., Denslow, N.D., Myers, M.S., Gross, T.S., & Tillitt, D.E. (2007). Biomarkers of contaminant exposure in northern pike (*Esox lucius*) from the Yukon River Basin, Alaska. *Archives of environmental contamination and toxicology*, 52(4), 549-562. <https://doi.org/10.1007/s00244-006-0134-z>
- Hirai, N., Nanba, A., Koshio, M., Kondo, T., Morita, M., & Tatarazako, N. (2006). Feminization of Japanese medaka (*Oryzias latipes*) exposed to 17 β -estradiol: Formation of testis-ova and sex-transformation during early-ontogeny. *Aquatic Toxicology*, 77(1), 78-86. <https://doi.org/10.1016/j.aquatox.2005.11.001>
- Hotos, G.N., Avramidou, D., & Ondrias, I. (2000). Reproduction biology of *Liza aurata* (Risso, 1810), (Pisces, Mugilidae) in the lagoon of Klisova (Messolonghi, W. Greece). *Fisheries Research*, 47(1), 57-67. [https://doi.org/10.1016/S0165-7836\(99\)00128-9](https://doi.org/10.1016/S0165-7836(99)00128-9)
- Imai, S., Koyama, J., & Fujii, K. (2005). Effects of 17 β -estradiol on the reproduction of Java-medaka (*Oryzias javanicus*), a new test fish species. *Marine Pollution Bulletin*, 51(8), 708-714. <https://doi.org/10.1016/j.marpolbul.2005.02.018>
- Jafri, S.I.H., & Ensor, D.M. (1979). Occurrence of an intersex condition in the roach *Rutilus rutilus* (L.). *Journal of Fish Biology*, 14(6), 547-549. <https://doi.org/10.1111/j.1095-8649.1979.tb03554.x>
- Jobling, S., Nolan, M., Tyler, C.R., Brighty, G., & Sumpter, J.P. (1998). Widespread sexual disruption in wild fish. *Environmental science & technology*, 32(17), 2498-2506. <https://doi.org/10.1021/es9710870>
- Kiparissis, Y., Balch, G.C., Metcalfe, T.L., & Metcalfe, C.D. (2003). Effects of the isoflavones genistein and equol on the gonadal development of Japanese medaka *Oryzias latipes*. *Environmental Health Perspectives*, 111(9), 1158.
- Koger, C.S., Teh, S.J., & Hinton, D.E. (2000). Determining the sensitive developmental stages of intersex induction in medaka (*Oryzias latipes*) exposed to 17 β -estradiol or testosterone. *Marine environmental research*, 50(1), 201-206. [https://doi.org/10.1016/S0141-1136\(00\)00068-4](https://doi.org/10.1016/S0141-1136(00)00068-4)
- Kojima, H., Katsura, E., Takeuchi, S., Niiyama, K., & Kobayashi, K. (2004). Screening for estrogen and androgen receptor activities in 200 pesticides by *in vitro* reporter gene assays using Chinese hamster ovary cells. *Environmental Health Perspectives*, 112(5), 524.
- Krisfalusi, M., & Nagler, J.J. (2000). Induction of gonadal intersex in genotypic male rainbow trout (*O. mykiss*) embryos following immersion in estradiol-17 β . *Molecular Reproduction and Development*, 56(4), 495-501. [https://doi.org/10.1002/1098-2795\(200008\)56:4<495::AID-MRD7>3.0.CO;2-E](https://doi.org/10.1002/1098-2795(200008)56:4<495::AID-MRD7>3.0.CO;2-E)
- Luther, G. (1977). New Characteristics for consideration in the taxonomic appraisal of grey mullets. *Journal of Marine Biological Association of India*, 19(1-2), 1-9.
- Matthiessen, P., Allen, Y., Bignell, J., Craft, J., Feist, S., Jones, G., ... & Stewart, C. (2002). Studies of endocrine disruption in marine fish-progress with the EDMAR programme. *ICES CM*.
- McDonough, C.J., Roumillat, W.A., & Wenner, C.A. (2003). Fecundity and spawning season of striped mullet (*Mugil cephalus* L.) in South Carolina estuaries. *Fishery Bulletin*, 101(4), 822-834.
- Mikaelian, I., De Lafontaine, Y., Harshbarger, J.C., Lee, L.L., & Martineau, D. (2002). Health of lake whitefish (*Coregonus clupeaformis*) with elevated tissue levels of environmental contaminants. *Environmental toxicology and chemistry*, 21(3), 532-541. <https://doi.org/10.1002/etc.5620210310>
- Nolan, M., Jobling, S., Brighty, G., Sumpter, J.P., & Tyler, C.R. (2001). A histological description of intersexuality in the roach. *Journal of Fish Biology*, 58(1), 160-176. <https://doi.org/10.1111/j.1095-8649.2001.tb00505.x>
- Orlando, E., Kolok, A., Binzcik, G., Gates, J., Horton, M., Lambright, C., ... & Guillette, L. (2004). Endocrine-Disrupting Effects of Cattle Feedlot Effluent on an Aquatic Sentinel Species, the Fathead Minnow. *Environmental Health Perspectives*, 112(3), 353-358. <https://doi.org/10.1289/ehp.6591>
- Peters, H.M. (1975). Hermaphroditism in cichlid fishes. In R. Reinboth (Ed.), *Intersexuality in the animal kingdom* (pp. 228-235). Springer Berlin Heidelberg. 452 pp.
- Purdom, C.E., Hardiman, P.A., Bye, V.V.J., Eno, N.C., Tyler, C.R., & Sumpter, J.P. (1994). Estrogenic effects of effluents from sewage treatment works. *Chemistry and Ecology*, 8(4), 275-285. <http://dx.doi.org/10.1080/02757549408038554>
- Puy-Azurmendi, E., Ortiz-Zarragoitia, M., Villagrasa, M., Kuster, M., Aragón, P., Atienza, J., ... & Fernandes, D. (2013). Endocrine disruption in thicklip grey mullet (*Chelon labrosus*) from the Urdaibai Biosphere Reserve (Bay of Biscay, Southwestern Europe). *Science of the Total Environment*, 443, 233-244. <https://doi.org/10.1016/j.scitotenv.2012.10.078>
- Scott, D.B.C. (1975). A hermaphrodite specimen of *Coregonus lavaretus* (L.) (Salmoniformes, Salmonidae) from Loch Lomond, Scotland. *Journal of Fish Biology*, 7(5), 709-709. <https://doi.org/10.1111/j.1095-8649.1975.tb04642.x>
- Smith, C.L. (1971). A revision of the American groupers: *Epinephelus* and allied genera. *Bulletin of the AMNH*; v. 146, article 2.
- Srivastava, S.S., & Sathyanesan, A.G. (1971). Gonadal changes in response to radio thyroidectomy and thiourea treatment in *Mystus vittatus* (Bloch). *Anatomischer Anzeiger*, 129(2), 183.
- Stentiford, G., & Feist, S. (2005). First reported cases of intersex (ovotestis) in the flatfish species dab *Limanda limanda*: Dogger Bank, North Sea. *Marine Ecology Progress Series*, 301, 307-310. <https://doi.org/10.3354/meps301307>
- Tancioni, L., Caprioli, R., Al-Khafaji, D., Hantoosh, A., Mancini, L., Boglione, C., ... & Cataudella, S. (2016). Anthropogenic threats to fish of interest in aquaculture: Gonad intersex in a wild population of thinlip grey mullet *Liza ramada* (Risso, 1827) from a polluted estuary in central Italy. *Aquaculture Research*, 47(5), 1670-1674. <https://doi.org/10.1111/are.12604>
- Tyler, C.R., & Jobling, S. (2008). Roach, sex, and gender-bending chemicals: The feminization of wild fish in English rivers. *Bioscience*, 58(11), 1051-1059. <https://doi.org/10.1641/B581108>
- Van Oordt, G. J. (1933). Zur sexualität der gattung *Epinephelus* (Serranidae, Teleostei). *Z Mikr Anat Forsch*, 33, 525-533.
- Waltham, N.J., Teasdale, P.R., & Connolly, R.M. (2013). Use of flathead mullet (*Mugil cephalus*) in coastal biomonitor studies: Review and recommendations for future studies. *Marine pollution bulletin*, 69(1), 195-205. <https://doi.org/10.1016/j.marpolbul.2013.01.012>

- Whitfield, A. K., Elliott, M., Basset, A., Blaber, S. J. M., & West, R. J. (2012). Paradigms in estuarine ecology—a review of the Remane diagram with a suggested revised model for estuaries. *Estuarine, Coastal and Shelf Science*, 97, 78-90.
<https://doi.org/10.1016/j.ecss.2011.11.026>
- Zhan, W., Xu, Y., Li, A.H., Zhang, J., Schramm, K.W., & Kettrup, A. (2000). Endocrine disruption by hexachlorobenzene in Crucian carp (*Carassius auratus gibelio*). *Bulletin of environmental contamination and toxicology*, 65(5), 560-566.
<https://doi.org/10.1007/s001280000160>