

Localized Amyloid-like Accumulation in a Zebrafish (*Danio rerio*): A Case Report

Aykut Ulucan^{1,*} , Hayati Yuksel²

¹Bingöl University, Vocational School of Health Services, Department of Medical Services and Techniques, 12000, Bingöl, Turkey.

² Bingöl University, Faculty of Veterinary, Medicine Department of Pathology, 12000, Bingöl, Turkey.

Article History

Received 24 April 2018
Accepted 09 April 2019
First Online 10 April 2019

Corresponding Author

Tel.: +904262160012
E-mail: aulucan@bingol.edu.tr

Keywords

Amyloid
Amyloidosis
Peritoneal
Immunohistochemistry
Histopathology

Abstract

Amyloidosis is described as collection of extracellular proteins with a characteristic fibrillar form with electron microscopy, a typical X-ray diffraction pattern and a green reflection with Congo red affinity. Zebrafish is an appropriate model organism for studying developmental immunology for modeling many infectious disorders. We observed that localized amyloid-like deposition was in the peritoneal membrane which is showing greenish reflection in the polarized filter with Congo red staining and immuno-positive staining with primary antibody of amyloid precursor protein. Consequently, in this case report, we demonstrated that incidentally detected and rarely seen localized amyloid-like accumulation in a zebrafish.

Introduction

Nomenclature Committee of the International Society of Amyloidosis described the amyloidosis, as "a collection of extracellular proteins with a characteristic fibrillar form with electron microscopy, a typical X-ray diffraction pattern and a green reflection with Congo red affinity" (Westermarck *et al.*, 2005). Amyloidosis is identified as the typical apple-green birefringence appearance examined under polarized light of tissues stained with Congo red. Amyloidosis is reserved into systemic and localized types. The localized amyloid types were seen limited to a single tissue, organ, or a body part (Meijer *et al.*, 2008).

Zebrafish is an appropriate model organism for studying developmental immunology. Its significant characteristics for various studies also for modeling

many infections which is affecting fish (Chinchilla, Encinas, Estepa, Coll, & Gomez-Casado, 2015; López-Muñoz, Roca, Sepulcre, Meseguer, & Mulero, 2010; Rowe, Withey, & Neely, 2014) and humans (Acik, Yuksel, Ulucan & Cetinkaya, 2016; Goody, Sullivan, & Kim, 2014).

Localized amyloid-like accumulations are seen rarely and have limited information about amyloidosis in zebrafish and other teleost species (Mashima, Cornish & Lewbart 1997; Russell *et al.*, 2014). In our project we researched immunohistochemical and serologic investigation of TNF- α (tumor necrosis factor-alpha) and Serum Amyloid A (SAA) levels in zebrafish (*Danio rerio*) and their effects on immune system. In this case report, incidentally we found that in the late phase group of experiment there was localized amyloid accumulation in one of one hundred and twenty zebrafish.

Materials and Methods

The main material of this case report was a one year old wild-type zebrafish (*Danio rerio*).

Zebrafish Care and Maintenance

Care and feeding of zebrafish followed established protocols (Westerfield, 2000).

Preparation of Emulsion and Injection

In our project, 120 fish have injected intraperitoneally with a dose of 5 µl emulsion of Complete Freund's Adjuvant (CFA) (F5881-10X, Sigma, USA) and Keyhole Limpet Hemocyanin (KLH) (H7017, Sigma) (1 mg KLH mixed in 1 ml CFA). Injections have applied into the midline of the pelvic fins (Kinkel, Eames, Philipson, & Prince, 2010; Lugo-Villarino *et al.*, 2010; Page *et al.*, 2013) at the 0 and 14 days of experiment.

Anesthesia, Necropsy and Histopathological Examination

At the end of the 49th day, fish were anesthetized with using a dose of 0.168 mg/ml Tricaine methanesulfonate (TMS), Tricaine-S® (Western Chemical, Inc., Ferndale, Washington) in distilled water. After the fish was euthanized by using the over dose of TMS and systemic necropsy was made to all fish, all tissue samples are taken and placed in Davidson's fixative for 12 h, and then in 10% buffered formaldehyde (Matthews & Varga, 2012; Mumford, 2004). Tissues were processed routinely, embedded in paraffin, sectioned at 5 µm thicknesses by rotary microtome (Leica, RM2125) and slides were stained with haematoxylin and eosin (H&E) (Bancroft & Gamble, 2002) and Congo red (Vowles, 2008) for histopathological examination. The presence of amyloid deposits in tissue were demonstrated by using the primary anti-beta-APP770, primary antibody (PA5-32262, Thermo Fisher Scientific, USA) and DAB (3,3'-Diaminobenzidine) chromogen (D7304, Sigma, Germany) with Streptavidin-Biotin-Peroxidase Complex method by immunohistochemically (Hsu, Raine, & Fanger, 1981). Finally, the slides were examined and checked for presence of amyloid, photographed by using light microscope with attached polarizing filter and imaging system (BX43, DP74, Olympus, Germany).

Results

Macroscopic Findings

At the necropsy, adhesions were seen in the intraperitoneal area and between the visceral organs and peritoneal thickening was observed.

Histopathologic findings

Histopathologically, localized amyloid-like deposition which is surrounded by connective tissue was observed incidentally in the peritoneal membrane in dorsal-caudal abdominal cavity in one of 120 zebrafish. Inflammatory cells infiltration composed of mainly mononuclear cells (peritoneal macrophages) and fibrosis which were seen especially in region of the injection at the dorsal-caudal abdominal cavity. In addition to this, greenish (apple-green) reflection was observed in the extracellularly localized amyloid-like accumulation (amorphous appearance material) with the polarized filter imaging by Congo red staining. Immunohistochemically, amyloid-like deposits were shown positive staining (Figure 1A, B, C & D). In control fish, peritoneal membrane tissues were shown normal histological structure and amyloid accumulation not observed with immunohistochemical or Congo red staining (Figure 1E, F, G & H). In all fish, there were not seen any presence of amyloid deposits in other tissues or organs.

Discussion

Amyloidosis is a term for diseases that share a single common property: extracellular deposition of pathologic insoluble fibrillar proteins. Thirty amyloid fibril proteins have been described in humans as well as 10 amyloid fibril proteins in animals (Sipe *et al.*, 2012; Westermark *et al.*, 2007). Today, only in localized amyloid deposits, less than 13 amyloid fibril proteins have been identified (Sipe *et al.*, 2010) and more are expected to be discovered (Westermark & Westermark, 2011).

Amyloidosis may be occur related chronic inflammatory or neoplastic diseases, but in many instances, no predisposing factor is found (Kumar, Abbas, Fausto, & Aster, 2014). Although there were chronic inflammatory lesions (fibrosis, infiltration of macrophages) in this case, no septicemia and widespread acute inflammatory lesions or neoplastic disease were observed. Amyloidosis has been reported rarely in elasmobranchs (Camus, Brown, Field, & McDermott, 2016) and some teleost fishes (Mashima, Cornish & Lewbart, 1997; Russell *et al.*, 2014). In these previously reported cases, amyloid formation has been attributed to septicemic, neoplastic and idiopathic causes. But amyloidosis has not been previously reported in zebrafish.

Amyloidosis can be also identified by affinity for the dye Congo red with concomitant greenish–yellow birefringence and a typical fibrillar ultrastructure (Vowles, 2008; Westermark & Westermark, 2011). In our case report, the presence of localized amyloid-like accumulation which is showing greenish reflection in the polarized filter with Congo red staining was remarkable and it has been previously observed in two different teleost species (Mashima, Cornish & Lewbart, 1997;

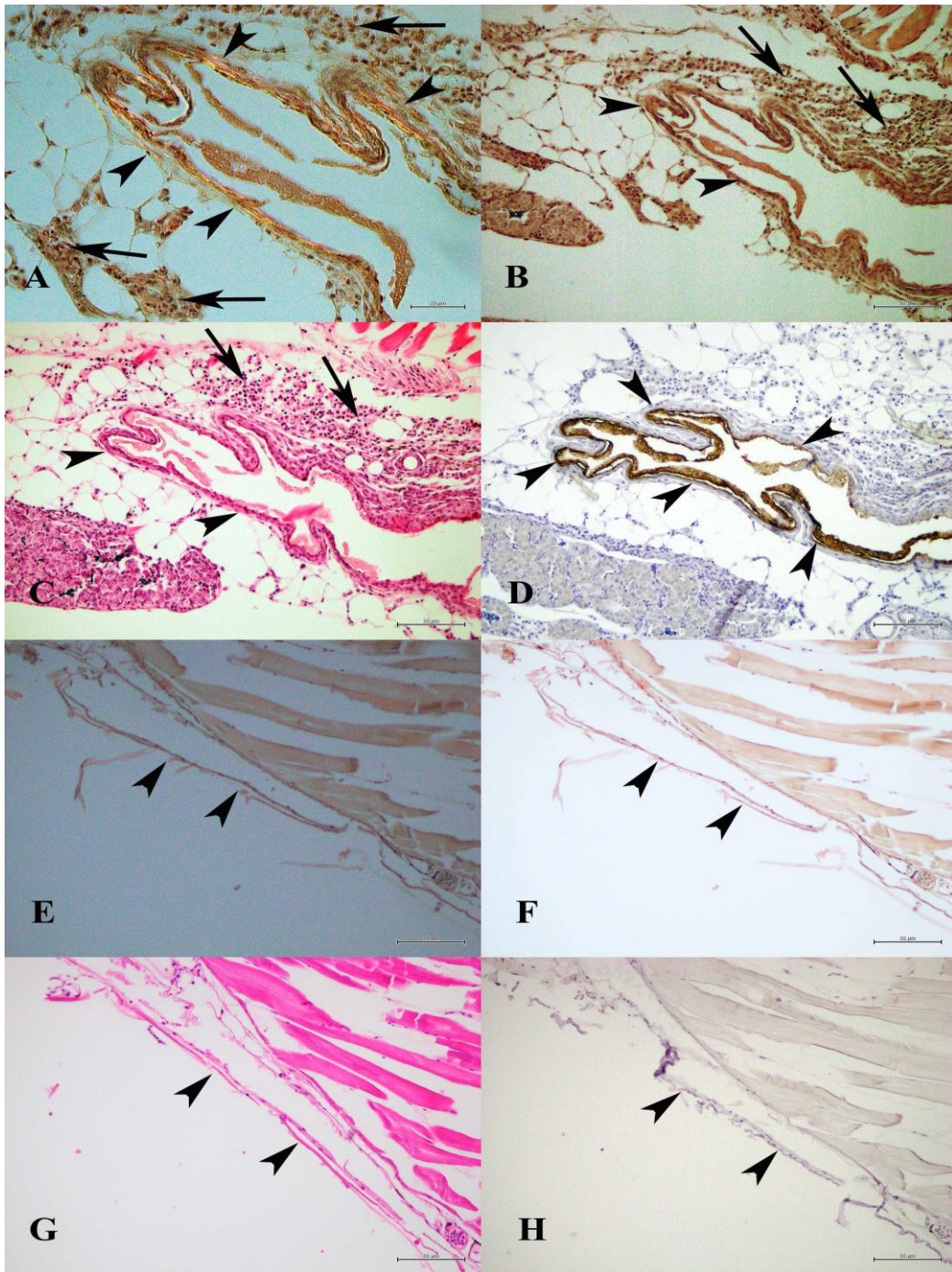


Figure1. Localized amyloid-like accumulation in the peritoneum membrane. Inflammatory cells infiltration mainly macrophages (arrows); the presence of localized amyloid-like accumulation which is showing greenish reflection (arrow heads) in the polarized filter with Congo red staining, 400x magnification (A). Inflammatory cells infiltration mainly macrophages (arrows); accumulation of the amorphous appearance material with red colored (arrow heads) in the non-polarized image with Congo red staining, 200x magnification (B). Inflammatory cells infiltration composed of macrophages (arrows); accumulation of the amorphous appearance material with red colored (arrow heads), H&E staining, 200x magnification (C). Positive stained areas with Amyloid precursor protein primary antibody (arrow heads), immunohistochemical staining, 200x magnification (D). Peritoneal membrane tissue of control fish, which is showing normal histological structure (arrow heads) with H&E staining (G), and amyloid accumulation not observed with immunohistochemically (H) or Congo red staining and in the polarized filter (E, F) 200x magnification.

Russell *et al.*, 2014). In H&E staining, amyloid appears as an amorphous and eosinophilic structure (Kumar, Abbas, Fausto, & Aster, 2014). Histopathologically, localized amyloid-like deposition was seen in the

peritoneal membrane in dorsal-caudal abdominal cavity at the injection area in one fish. The presence of that localized amyloid-like accumulation may be due to idiopathic or chronic inflammatory reasons in the

injection site of the peritoneum. Immunohistochemistry may be used to detect amyloid subtypes, while there are few useful antibodies between them (Penner & Müller, 2006). In this study, anti-beta-APP770 primary antibody (Predicted to recognize Amyloid precursor protein) was employed and showed positivity in immunohistochemical staining. Immuno-positive stained areas were shown immunohistochemically (Figure 1A, B, C & D). Those findings were showing similar condition with identified amyloid deposits. Ultrastructurally, all forms of amyloid are composed of continuous, non-branching, 7.5- to 12-nm fibrils (Cheville, 2009). But we did not have the possibility of electron microscopic examination due to technical difficulties.

Presence of amyloid deposits in mammals is closely related to APP. Acute phase response (APR) in zebrafish, including the discovery of a number of APPs similar to mammals (SAA, hepcidin and haptoglobin, etc.) and a resemble system for the induction of APPs and dramatically similar to that in human and mouse (Lin *et al.*, 2007; Sun, Li, & Zhang, 2014). SAA related reactive, secondary or AA amyloidosis is a major form of amyloidosis in higher vertebrates associated with chronic inflammatory processes (Kumar, Abbas, Fausto, & Aster, 2014). SAA has been identified in most vertebrates, including teleosts, but has yet to be identified in elasmobranchs (Uhlir & Whitehead, 1999). Amyloid P, which can make up 14% of the dry weight of amyloid deposits in mammals, has been identified in elasmobranchs (Robey, Tanaka & Liu 1983) and it has been suggested in the pathogenesis of one case (Camus, Brown, Field, & McDermott, 2016). On the other hand, 10 amyloid fibril protein types have been described in animals and the one of the most seen of these amyloid beta (A β) fibrils were observed in localized amyloidosis types (Sipe *et al.*, 2012; Westermarck *et al.*, 2007). There have been many studies on Alzheimer's disease and beta-Amyloid precursor protein in zebrafish (Banote *et al.*, 2016; Bhattarai *et al.*, 2016; Newman *et al.*, 2010). The specific type of amyloid-like fibrils and effective factors related in this case are unknown, but in the light of these informations, we can suggest that hypothetically the A β fibrils or acute-phase protein SAA is the precursor protein found in amyloid A (AA).

Consequently, in this case report, we demonstrated that localized amyloid-like accumulation fact in zebrafish for the first time. For this reason, there are more detailed investigations must be need to defined of the formation of amyloidosis and determined to sub-types of amyloid fibrils in zebrafish.

Acknowledgements

This study was supported by The Scientific and Technological Research Council of Turkey (TÜBİTAK) Project number: 215Z467 within the Ministry of Science, Industry and Technology of Republic of Turkey.

Permission of the Ethics Committee

Bingöl University Animal Experiments Local Ethics Committee meeting was dated 26.09.2014 with the meeting number 2014/09 and the necessary permission was taken within the decision number 09/02.

References

- Acik, M. N., Yuksel, H., Ulucan, A., & Cetinkaya, B. (2016). The first experimental research on the pathogenicity of *Arcobacter butzleri* in zebrafish. *Veterinary Microbiology*, 189, 32-38. <https://doi.org/10.1016/j.vetmic.2016.04.016>
- Bancroft, J., & Gamble, M. (2002). *Theory and practice of histological techniques*, 5th Ed., Churchill Livingstone, EUA.
- Banote, R. K., Edling, M., Eliassen, F., Kettunen, P., Zetterberg, H., & Abramsson, A. (2016). B-amyloid precursor protein-b is essential for mauthner cell development in the zebrafish in a notch-dependent manner. *Developmental biology*, 413(1), 26-38. <https://doi.org/10.1016/j.ydbio.2016.03.012>
- Bhattarai, P., Thomas, A. K., Cosacak, M. I., Papadimitriou, C., Mashkaryan, V., Froc, C., . . . Zhang, Y. (2016). Il4/stat6 signaling activates neural stem cell proliferation and neurogenesis upon amyloid- β 42 aggregation in adult zebrafish brain. *Cell reports*, 17(4), 941-948. <https://doi.org/10.1016/j.celrep.2016.09.075>
- Camus, A., Brown, C., Field, C., & McDermott, A. (2016). Amyloid-like renal lesions in a rougthead stingray *Dasyatis centroura* (Mitchill 1815). *Journal of Fish Diseases*, 39, 613-617. <https://doi.org/10.1111/jfd.12397>
- Cheville, N. F. (2009). *Amyloid protein misfolding defects, and inclusions. Ultrastructural Pathology*, 2nd edn, 829-855. Wiley-Blackwell, Ames, IA.
- Chinchilla, B., Encinas, P., Estepa, A., Coll, J. M., & Gomez-Casado, E. (2015). Transcriptome analysis of rainbow trout in response to non-virion (nv) protein of viral haemorrhagic septicaemia virus (vhsv). *Applied Microbiology and Biotechnology*, 99(4), 1827-1843. <http://dx.doi.org/10.1007/s00253-014-6366-3>
- Goody, M. F., Sullivan, C., & Kim, C. H. (2014). Studying the immune response to human viral infections using zebrafish. *Developmental & Comparative Immunology*, 46(1), 84-95. <https://doi.org/10.1016/j.dci.2014.03.025>
- Hsu, S.-M., Raine, L., & Fanger, H. (1981). Use of avidin-biotin-peroxidase complex (abc) in immunoperoxidase techniques: A comparison between abc and unlabeled antibody (pap) procedures. *Journal of Histochemistry & Cytochemistry*, 29(4), 577-580. <https://doi.org/10.1177/29.4.6166661>
- Kinkel, M. D., Eames, S. C., Philipson, L. H., & Prince, V. E. (2010). Intraperitoneal injection into adult zebrafish. *Journal of visualized experiments: JoVE*(42). <https://doi.org/10.3791/2126>
- Kumar, V., Abbas, A. K., Fausto, N., & Aster, J. C. (2014). *Robbins and cotran pathologic basis of disease, professional edition e-book*: elsevier health sciences.
- Lin, B., Chen, S., Cao, Z., Lin, Y., Mo, D., Zhang, H., . . . Xu, A. (2007). Acute phase response in zebrafish upon aeromonas salmonicida and staphylococcus aureus infection: Striking similarities and obvious differences

- with mammals. *Molecular immunology*, 44(4), 295-301. <https://doi.org/10.1016/j.molimm.2006.03.001>
- López-Muñoz, A., Roca, F. J., Sepulcre, M. P., Meseguer, J., & Mulero, V. (2010). Zebrafish larvae are unable to mount a protective antiviral response against waterborne infection by spring viremia of carp virus. *Developmental & Comparative Immunology*, 34(5), 546-552. <https://doi.org/10.1016/j.dci.2009.12.015>
- Lugo-Villarino, G., Balla, K. M., Stachura, D. L., Bañuelos, K., Werneck, M. B., & Traver, D. (2010). Identification of dendritic antigen-presenting cells in the zebrafish. *Proceedings of the National Academy of Sciences*, 107(36), 15850-15855. <https://doi.org/10.1073/pnas.1000494107>
- Mashima, T. Y., Cornish, T. E. & Lewbart, G. A. (1997). Amyloidosis in a jack dempsey cichlid, *Cichlasoma biocellatum* Regan. *Journal of Fish Diseases* 20, 73-75. <https://www.sciencebase.gov/catalog/item/5053a44ee4b097cd4fce93a8>
- Matthews, M., & Varga, Z. M. (2012). Anesthesia and euthanasia in zebrafish. *ILAR journal*, 53(2), 192-204. <https://doi.org/10.1093/ilar.53.2.192>
- Meijer, J. M., Schonland, S. O., Palladini, G., Merlini, G., Hegenbart, U., Ciocca, O., . . . Hazenberg, B. P. (2008). Sjögren's syndrome and localized nodular cutaneous amyloidosis: Coincidence or a distinct clinical entity? *Arthritis & Rheumatology*, 58(7), 1992-1999. <https://doi.org/10.1002/art.23617>
- Mumford, S. L. (2004). Histology of finfish. *USFWS, Olympia Fish Health Center. Olympia. Washington.*
- Newman, M., Wilson, L., Camp, E., Verdile, G., Martins, R., & Lardelli, M. (2010). A zebrafish melanophore model of amyloid β toxicity. *Zebrafish*, 7(2), 155-159. <https://doi.org/10.1089/zeb.2009.0628>
- Page, D. M., Wittamer, V., Bertrand, J. Y., Lewis, K. L., Pratt, D. N., Delgado, N., . . . Doty, A. (2013). An evolutionarily conserved program of b-cell development and activation in zebrafish. *Blood*, 122(8), e1-e11. <https://doi.org/10.1182/blood-2012-12-471029>
- Penner, C. R., & Müller, S. (2006). Head and neck amyloidosis: A clinicopathologic study of 15 cases. *Oral oncology*, 42(4), 421-429. <https://doi.org/10.1016/j.oraloncology.2005.09.010>
- Robey, F. A., Tanaka, T. & Liu, T. H. (1983). Isolation and characterization of two major serum proteins from the dogfish, *Mustelus canis*, C-reactive protein and amyloid P component. *Journal of Biological Chemistry* 258, 3889-3894. <http://www.jbc.org/content/258/6/3889>
- Rowe, H. M., Withey, J. H., & Neely, M. N. (2014). Zebrafish as a model for zoonotic aquatic pathogens. *Developmental & Comparative Immunology*, 46(1), 96-107. <https://doi.org/10.1016/j.dci.2014.02.014>
- Russell, S., Tubbs, L., McLelland, D. J., LePage, V., Young, K. M., Huber, P. & Lumsden, J. S. (2014). Amyloid associated with neoplasia in two captive tricolour sharkminnows *Balantiocheilus melanopterus* Bleeker. *Journal of Fish Diseases* 38, 561-565. <https://doi.org/10.1111/jfd.12266>
- Sipe, J. D., Benson, M. D., Buxbaum, J. N., Ikeda, S.-I., Merlini, G., Saraiva, M. J., & Westermark, P. (2010). Amyloid fibril protein nomenclature: 2010 recommendations from the nomenclature committee of the international society of amyloidosis. *Amyloid*, 17(3-4), 101-104. <https://doi.org/10.3109/13506129.2010.526812>
- Sipe, J. D., Benson, M. D., Buxbaum, J. N., Ikeda, S.-i., Merlini, G., Saraiva, M. J., & Westermark, P. (2012). Amyloid fibril protein nomenclature: 2012 recommendations from the nomenclature committee of the international society of amyloidosis. *Amyloid*, 19(4), 167-170. <https://doi.org/10.3109/13506129.2012.734345>
- Sun, W., Li, Z., & Zhang, S. (2014). Acute phase response in zebrafish embryo/larva with special emphasis on lps-induced changes in expression pattern of acute phase protein genes. *Journal of the Marine Biological Association of the United Kingdom*, 94(7), 1569-1580. <https://doi.org/10.1017/S0025315414000150>
- Uhlar, C. M., & Whitehead, A. S. (1999). Serum amyloid A, the major vertebrate acute-phase reactant. *European Journal of Biochemistry* 265, 501-523. <https://doi.org/10.1046/j.1432-1327.1999.00657.x>
- Vowles, G. H. (2008). Amyloid. In: *Theory and Practice of Histological Techniques*. 6th edn (ed. by J.D. Bancroft & M. Gamble), pp. 261-281. Elsevier Ltd., Philadelphia, PA.
- Westerfield, M. (2000). *The zebrafish book. A guide for the laboratory use of zebrafish (Danio rerio)*, 4th ed. University of Oregon Press, Eugene.
- Westermark, G. T., & Westermark, P. (2011). Localized amyloids important in diseases outside the brain—lessons from the islets of langerhans and the thoracic aorta. *The FEBS Journal*, 278(20), 3918-3929. <https://doi.org/10.1111/j.1742-4658.2011.08298.x>
- Westermark, P., Benson, M. D., Buxbaum, J. N., Cohen, A. S., Frangione, B., Ikeda, S.-I., . . . Sipe, J. D. (2005). Amyloid: Toward terminology clarification report from the nomenclature committee of the international society of amyloidosis. *Amyloid*, 12(1), 1-4. <https://doi.org/10.1080/13506120500032196>
- Westermark, P., Benson, M. D., Buxbaum, J. N., Cohen, A. S., Frangione, B., Ikeda, S.-I., . . . Sipe, J. D. (2007). A primer of amyloid nomenclature. *Amyloid*, 14(3), 179-183. <https://doi.org/10.1080/13506120701460923>