



Brain and Liver Histopathological Examination of *Carassius gibelio* from A Newly Reconstructed Lake with Toxic Cyanobacteria

Panagiotis Berillis^{1,*}, Theodoti Papadimitriou^{1,2}, Evi Petridou¹, Kormas Konstantinos¹, Kagalou Ifigenia^{1,2}

¹ University of Thessaly, School of Agricultural Sciences, Department of Ichthyology and Aquatic Environment, Fytoko Street, 38 445, Nea Ionia Magnesia, Greece.

² Management Body of Ecodevelopment Area of Karla, Mavrovouni, Kefalovriso, Velestino, Stefanovikio, 37500, Greece.

* Corresponding Author: Tel.: +30.242 1093248; Fax: +30.242 1093248;
E-mail: pveril@uth.gr

Received 7 November 2013
Accepted 27 February 2014

Abstract

Lake Karla, Greece, is a partially reconstructed lake. The lake's water filling process started in September 2009. Existing evidence based on the prevailing microorganisms and cyanotoxin levels in the lake in 2010 suggested that the lake could have a negative effect on its biota. By investigating whether *Carassius gibelio* individuals bear brain and liver histopathological findings, this study complements the data now available from the first year of L. Karla's reconstruction. Based on the 16S rRNA gene diversity, the potentially toxic cyanobacteria *Anabaenopsis* sp. and *Planktothrix* were shown to be present in the lake's water in May 2011. *C. gibelio* specimens were collected a month later. Histopathological alterations in the liver of the individuals, namely picnotic nuclei, loss of structure and hemorrhagic regions, were detected by microscopic examination. Picnotic nuclei, loss of the liver structure and hemorrhagic regions were detected. These alterations may be associated with the occurrence of cyanobacterial toxins possibly produced by the potentially toxic cyanobacterial species found in the water column. No alterations were found in the brain, probably due to the existence of the blood-brain barrier.

Keywords: Brain, *Carassius gibelio*, cyanobacterial toxins, Lake Karla, liver.

Introduction

Lake eutrophication is considered to be a major worldwide problem as it is accompanied with frequent and heavy cyanobacterial blooms. Lake eutrophication is considered to be a major worldwide problem associated with water quality degradation. It is often accompanied by frequent and heavy cyanobacterial blooms, which may be dominated by potentially toxic species (Bartram *et al.*, 1999). Exposure to cyanotoxins represents a health risk to aquatic organisms, wildlife, domestic animals and humans through drinking, ingestion or contact with either cyanobacteria and/or the toxins from the water (Dietrich and Hoeger, 2005). Despite this, cyanotoxins production is one of the most successful ecological strategies for cyanobacteria.

The most widely distributed cyanobacterial genera that include potentially toxic species are *Anabaena*, *Aphanizomenon*, *Cylindrospermopsis*, *Lyngbya*, *Microcystis*, *Nodularia*, *Nostoc* and *Planktothrix* (Carmichael *et al.*, 2001). These microorganisms may produce different kinds of toxins, such as hepatotoxins and neurotoxins (Chorus, 2001). Hepatotoxins, and especially microcystins (MCYSTs) are mainly produced by the genera of

Microcystis, *Anabaena* and *Planktothrix* (Codd, 1995) and are at the present the most well investigated cyanotoxins (Welker *et al.*, 2004) with a cosmopolitan distribution. Most of the available information mainly focuses on acute toxicosis, resulting irreversible effects on many tissues such as liver, kidney, muscle, gonads and intestine (Fisher and Dietrich, 2000a; 2000b; Lang *et al.*, 2006; Li *et al.*, 2007). Although long-term toxicosis is comparatively understudied, histopathological alterations are reported (Dietrich and Hoeger, 2005; Huisman *et al.*, 2005).

During the last decades, eutrophication of Greek lakes has been the consequence of a number of human activities resulting in increased nutrient input. Frequent and prolonged cyanobacterial blooms have been reported in several Greek lakes (Vardaka *et al.*, 2005, Kagalou *et al.*, 2012, Katsiapi *et al.*, 2013), most of them being hepatotoxic (Cook *et al.*, 2004).

Lake Karla (Central Greece) is one of the very few examples of a reconstructed lake ecosystem. A shallow lake, which had dried up in the 1960s, has now been reconstructed establishing a 'new' ecosystem. During the first two years of the lake's water filling process (2009-2011), frequent extensive cyanobacterial blooms occurred dominated by species able to produce toxins MCYST included, both of

which were found in *Cyprinus carpio* (common carp) tissues (Mitsoura *et al.*, 2013; Papadimitriou *et al.*, 2013). Moreover, during the same period, a few incidents of mass fish kills were reported, possibly associated with parasitic/toxic unicellular eukaryotes (Oikonomou *et al.*, 2012; Nikouli *et al.*, 2013). Fishing activities in Lake Karla have been in revival since its reconstruction's initiation. *Carassius gibelio* (Prussian carp) and *C. carpio* are the main commercial fish species of the lake. In this paper we aimed at detecting brain and liver histopathological findings in *C. gibelio* individuals associated with the lake's high toxic cyanobacterial occurrence.

Materials and Methods

Lake Karla is located in central Greece (39°29'02" N, 22°51'41" E). Formerly covering an area of ca. 180 km²; in 1962 it dried up as a result of a subterranean tunnel in the nearby Pagasitikos Gulf leaving only a small permanent marsh in its place. River Pinios and its flooding events, supplied the lake with water rich in nutrients (Chatzinikolaou *et al.*, 2010). Several biological, physical, and chemical criteria characterized the lake as eutrophic, but with high stability before its drainage (Ananiadis, 1959). The refilling of the lake started in September 2009 by inflowing water from the nearby River Pinios. At present, the new lake Karla covers an area of 38 km².

Five hundred (500) ml water samples were collected from a littoral sampling station and analyzed for microcystins and cyanobacteria diversity. MCYSTs were analyzed in two forms: dissolved in water; and cell-bound in seston. For cell-bound MCYST, the water sample was filtered by a Whatmann GF/C 0.45µm filter, which was immediately frozen at -20°C. MCYSTs was extracted from the filter paper by placement in 100% methanol, stirring overnight at room temperature (20-22°C), followed by centrifugation at 1300 x g for 15 min. Extraction procedure was repeated three times and the supernatants of the extractions were pooled. The organic solvent was removed by placing the extract under a nitrogen-stream. The concentrated sample extract remaining after removing of the organic solvent was subjected to an enzyme-linked immunosorbent assay (ELISA). Results were expressed as micrograms of cellular MCYSTs equivalents per Liter. For analysis of dissolved microcystins, the filtered water was applied directly to ELISA. A commercial ABRAXIS-Microcystin ELISA kit was used (520011, USA) following the instructions of the manufacturer. The ELISA is an indirect competitive method using the b-amino acid 6E-ADDA as the epitope for antibody recognition for the quantitative analysis of all the microcystin analogues and nodularins. It was assumed that all the MCYSTs analogues determined by ELISA had equivalent toxicity to MC-LR and results were expressed as micrograms of cellular MCYSTs

equivalents per litre.

A water sample of 200-250 ml was collected in a pre-sterilized plastic container. Upon return to the laboratory (<1 h from collection), the total volume was filtered through a 0.2 µm pore size Polycarbonate Isopore filter (Sartorius, Goettingen, Germany) after screening through a 180 µm mesh net to exclude larger eukaryotes and particles. The filtration was conducted under a low vacuum (≤150 mmHg) to prevent cell damage. Filters were stored immediately at -80°C until further analysis. DNA was extracted using the UltraClean Soil DNA isolation kit (MoBio Laboratories, Carlsbad CA, USA) according to the manufacturer's protocol after slicing the filter with a sterile scalpel. Bulk DNA concentration (11.5 ng/µl) was estimated by spectrophotometry (NanoDrop ND-1000, NanoDrop Technologies, Wilmington DE, USA). For PCR amplification (35 cycles) of the cyanobacterial 16S rDNAs, the Cyanobacteria-specific primers

CYA106f (5'-CGGACGGGTGAGTAACGCGTGA-3'),
CYA781r(a) (5'-GACTACTGGGGTATCTAATCCC
ATT-3'), and
CYA781r(b) (5'-GACTACAGGGGTATCTAATCC
CTTT-3')

were used (Nübel *et al.*, 1997). The whole procedure of cloning, sequencing, and phylogenetic analyses was performed according to Kormas *et al.* (2011).

Adult individuals of the species *Carassius gibelio*, with a weight range of 350.5-510.5 g were collected from Lake Karla, during the June 2011 sampling using a trammel net with a 60 mm inner and 300 mm outer mesh size. *Carassius gibelio* individuals after the experimental fishing were sacrificed by immersion in ice cold water (hypothermia) and were transferred to the laboratory in an icebox shortly after their death. Five of them were used for liver and brain histopathological observation. Samples from the liver and brain were subjected to light and scanning electron microscopy. For light microscopy, samples were first fixed in 10% buffered formalin for 24 h at 4°C and then immediately dehydrated in graded series of ethanol, immersed in xylol, and embedded in paraffin wax. Sections of 5-7µm were mounted. After they had been deparaffinized, the sections were rehydrated, stained with hematoxylin and eosin, and mounted with Cristal/Mount. All tissues were examined under a microscope (Pathological Microscope Radical RMH-4B) and any histological abnormalities were recorded. A digital camera adjusted to the microscope and the Future WinJoe (Future Optics SCI&Tech Co., Ltd) software, were used for acquiring histopathological images. For scanning, electron microscopy tissue specimens were prefixed in 2.5% glutaraldehyde in 0.1 M sodium cacodylate solution for 24 h at 4°C and post-fixed with immersion for 2 h at 4°C in 1% osmium tetroxide buffered in cacodylate. Dehydration in a graded alcohol series took place before the final dehydration in a critical point dryer (Bal-tec CPD

030). The specimens were covered with a thin layer of gold using a sputter coater (Bal-tec SCD 004), before their examination under a scanning electron microscope (Cambridge Stereoscan 240).

Results

In total, seven cyanobacteria phylotypes were identified (Tab. 1). Two of them were related to potentially toxic species of *Anabaenopsis* sp. and, the *Limnothrix/Planktothrix* group. MCYST was found in both the lake water and seston; with higher values in the latter (Table 1).

In the present study, brain histopathology of the

fish showed normal histological architect without any indication of deformities (Figure 1). The pia matter, the molecular layer, the granular layer and the pyramidal layer appeared normal with no signs of necrosis and no haemorrhagic symptoms. Lesions were revealed in the liver only, which appeared discolored and brittle with some haemorrhagic regions. There were also numerous histopathological lesions. Loss of architecture structure, local vacuolizations, focal necrosis, karyorrhexis, nuclei pyknosis and sporadic haemorrhagic symptoms (Figure 2) were observed. Distinct endothelial cells line sinusoids were observed, the Space of Disse, the zone between sinusoid cells and hepatocytes, appeared normal. In some cases hepatocyte cords with

Table 1. Cyanobacterial phylotypes found in the Lake Karla, Greece, water column, May 2011. Sequences have been submitted to GenBank and assignment of accession numbers is underway

Phylotype	Relative abundance	Closest relative (% similarity) GenBank accession No.	Source /Habitat	Reference	Closest known relative
KRL3-AM1	37.5%	Clone LiUU-11-276 (100%) (HQ386368)	Lake water	GENBANK , unpublished	<i>Anabaenopsis nadsonii</i> (100%) (FM177482)
KRL3-AM2	9.4%	<i>Oscillatoria</i> sp. (99%) (AJ133106)	Lake water	GENBANK , unpublished	-
KRL3-AM19	6.4%	Clone NV1_CYA_1_2 (99%) (FJ204888)	Lake water	GENBANK , unpublished	<i>Mastigocladopsis</i> sp. (89%) (DQ235802)
KRL3-AM11	3,1%	Clone SSW9Ap (98%) (EU592382)	Brackish waters	Dillon <i>et al.</i> (2009)	<i>Limnothrix</i> sp. (92%) (AF212922)
KRL3-AM14	3.1%	<i>Symphyonemopsis</i> sp. (98%) (AJ544085)	Cave	Gügger <i>et al.</i> (2004)	-
KRL3-AM33	3.1%	Clone 4550-27F (99%) (FR648052)	Sea water	Sjostedt <i>et al.</i> (2012)	<i>Synechococcus</i> sp. (98%) (AY151238)
KRL3-AM6	3.1%	Clone 2S8 (99%) (GU074287)	Freshwater	Aizenberg-Gershtein <i>et al.</i> (2012)	-

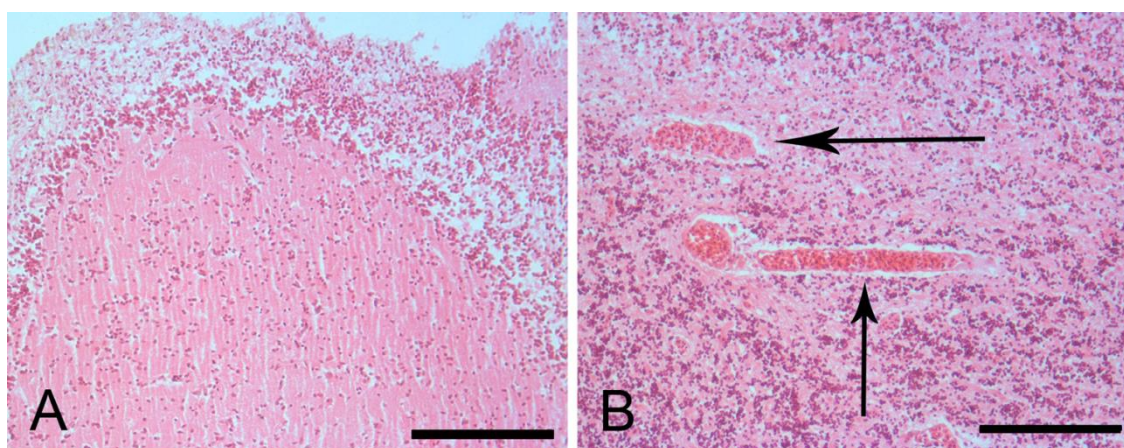


Figure 1. Histological sections of *Carassius gibelio*'s brain. A. The brain tissue showed normal histological architect without any indication of deformities. B. No erythrocytes were detected in the outer space of the brain blood vessels (arrows). Bar=100 µm.

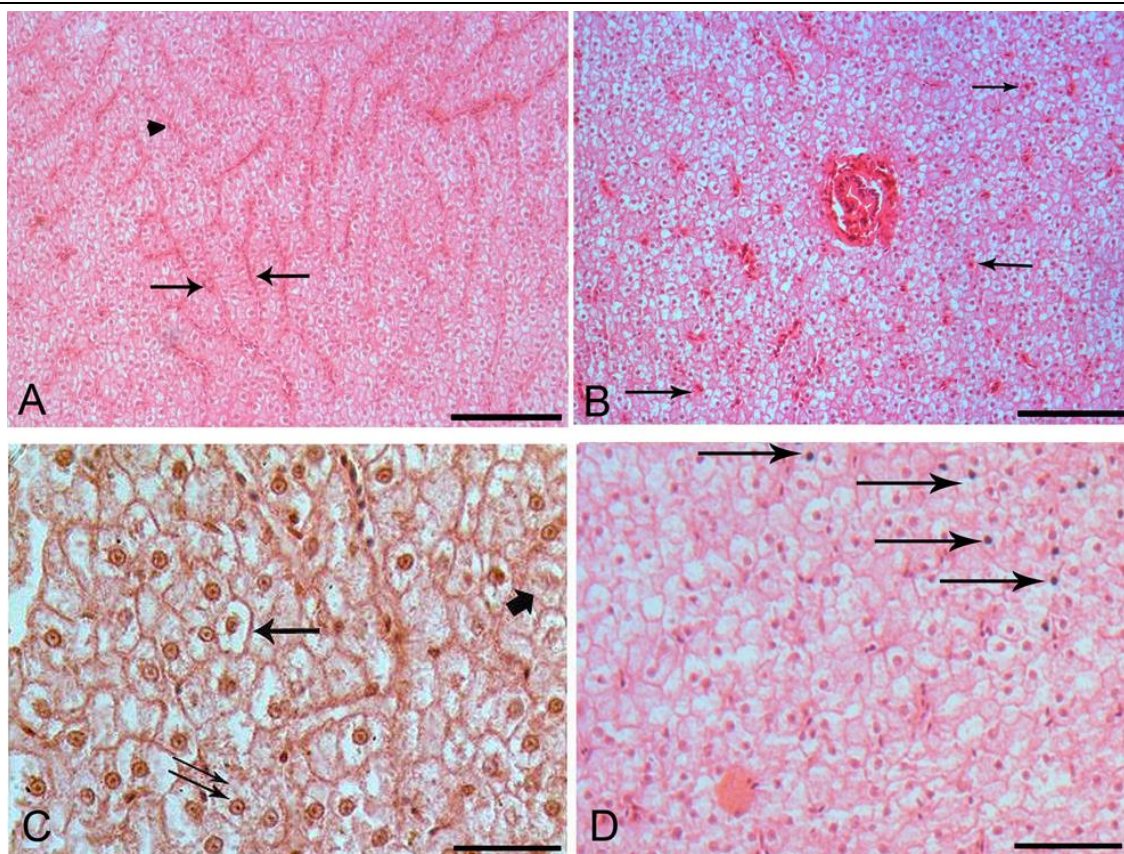


Figure 2. (A). Hyperplasia of hepatocytes in three-cell thick cords (between the arrows) separated by liver sinusoids containing erythrocytes (arrowhead). Bar=100 μ m. (B). The portal tract in the middle appeared to be normal without cirrhosis signs. Sporadic haemorrhagic symptoms (some of them are shown with arrows) and obvious vacuolization. Bar=100 μ m. (C). Normal cell (double arrow), extend vacuolization (arrow) and karyorrhexis (small arrow). Bar=30 μ m. (D). Signs of necrosis. Pycnotic nuclei are shown with arrows. Bar=40 μ m.

a thickness of three or more cells were noted. It can be signs of indicative hyperplasia or a possible early stage neoplasia. Hepatocytes contained large cytoplasmic vacuoles (clear regions in hepatocyte cytoplasm), while the portal tracks appeared to be normal without cirrhosis signs. Liver observation under the scanning electron microscope revealed damage to many of the cells' plasma membranes (Figure 3), which appeared to be broken and punctured on their surface (Figure 3). These cells can be described as necrotic cells.

Discussion

Lake Karla is already known to host intense cyanobacterial blooms, and the toxins produced have been found in *Cyprinus carpio* tissues (Papadimitriou *et al.*, 2013). For this reason, in this study we aimed at investigating whether there were any histopathological findings in another fish species existing in the lake, i.e. *Carassius gibelio*. At the same time, we confirmed the existence of potentially toxic cyanobacterial species by 16S rRNA gene diversity and measurement of MCYSTs concentrations, already known to prevail in the lake (Papadimitriou *et al.*, 2013).

A MCYSTs level of 20 μ g MCYST-LR /L

represents a guideline value for a moderate health risk in recreational waters (WHO, 1998). This concentration is equivalent to 100,000 cyanobacterial cells per ml, or approximately 50 μ g/L chlorophyll-a if cyanobacteria, and especially *Microcystis* sp. dominate. It is 20 times higher than the WHO provisional Guideline Value concentration for microcystin-LR drinking water of 1 μ g/L (WHO, 1998). MCYSTs values for Lake Karla (Table 2) were below the WHO Guide level for recreational waters, but much higher than the WHO Guide level for drinking water.

The water and seston MCYSTs concentrations, along with the existence of the two potentially toxic cyanobacterial phylotypes, raised two questions: a) whether *Carassius gibelio* individuals of the lake were affected and b) if yes, in what capacity?

C. gibelio is a member of the family Cyprinidae. It is not a widely commercial fish, but is consumed in many regions of Greece. It is omnivorous; feeding on plankton, zoobenthos, invertebrates, plant material, and detritus (Specziár *et al.*, 1997; 1998; Kottelat and Freyhof, 2007). However, as a result to its method of water filtration in order to obtain its main food source, large quantities of filamentous and colonial cyanobacteria often occur in its digestive tract (Kolmakov and Gladyshev, 2003). MCYSTs




Figure 3. A. Scanning electron micrograph of *Carassius gibelio* hepatocytes. Damages and holes (arrows) on the plasma membranes of the hepatocytes are obvious. B. A liver sinusoid (small arrow) under the scanning electron microscope. Erythrocytes are visible. Hepatocytes are separated from the sinusoids by the Space of Disse. Holes on the plasma membranes (arrow). C. High magnification of hepatocytes. Holes on the plasma membranes are obvious. D. Normal hepatocytes.

Table 2. MCYSTs concentrations during May and June 2011

Month	MCYST dissolved in water	MCYST cell-bound in seston
May	2.03 $\mu\text{g/L}$	4.19 $\mu\text{g/L}$
June	3.01 $\mu\text{g/L}$	5.50 $\mu\text{g/L}$

produced by cyanobacteria in aquatic environment have been proved to exert adverse effects on fish (Malbrouck and Kestemont, 2006). Fish are exposed to MCYSTs directly during feeding and/or passively during the continuous contact with their aquatic environment, while cyanobacterial metabolites are known to be transported through the aquatic food web (Xie *et al.*, 2004; Papadimitriou *et al.*, 2012). There are studies that have related lake and reservoir fish mortality to exposure in cyanobacterial hepatotoxins (Zurawell *et al.*, 2005; Malbrouck and Kestemont, 2006). Cyano-toxicity results in two possible types of structural changes: a) direct toxic effect of the pollutant leading to tissue degeneration and necrosis, and b) development of compensatory mechanisms such as cellular hyperplasia to deal with the stressor (Li *et al.*, 2007). Histopathology is a useful tool to assess the degree of toxicity.

It is well documented that the primary target organ for MCYSTs accumulation is the liver (Ernst,

2008; Moutou *et al.*, 2012; Papadimitriou *et al.*, 2012). Very few, *in vivo*, studies are available on the toxic effects of MCYSTs on fish's hepatocyte ultrastructure. Our main histological liver findings were a loss of architecture structure, local vacuolization, and focal necrosis with nuclei pyknosis, karyorrhexis, and sporadic haemorrhagic symptoms. All these alterations have been reported as signs of the intra-peritoneal effect of microcystins in many organs (liver included) of different fish species (Rabergh *et al.*, 1991; Kotak *et al.*, 1996; Carbis *et al.*, 1996; 1997; Fournie and Courtney, 2002). The fact that hepatocyte cords with thicknesses of three or more cells were observed, leads to the conclusion of hyperplasia or a possible liver neoplasia. The hepatocyte cords in fish are normally two cells thick (Cooley *et al.*, 2000). Dos Santos and Bracarense (2008) mentioned that chronic exposure to MCYSTs can cause hepatic or intestinal neoplasia. It is very difficult to directly associate the histopathological

alterations that we observed exclusively with the presence of the microcystins. At present, Lake Karla remains an ecosystem under development, and its biological features like species richness and abundance of planktonic organisms, presence of harmful substances etc, other than the first year of the lake's refilling process (Oikonomou *et al.*, 2012, Papadimitriou *et al.*, 2013), are still unknown.

A recent study (Kagalou *et al.*, 2008a) reported on the concentrations of MCYSTs in the brain tissue of *C. gibelio* individuals from Lake Pamvotis, Greece. Although in our study we did not quantify the MCYSTs concentration in the brain tissue of *C. gibelio* individuals, no histopathological alteration were detected. MCYST are expected to reach the brain tissue through blood circulation. The fact that the brain appeared not to be affected may be due to the effect of the blood-brain barrier existence. This "barrier" results from the selectivity of the tight junctions between endothelial cells in central nervous system vessels that restricts the passage of large or hydrophilic molecules. MCYSTs molecular weight is about 1000 daltons. This renders MCYSTs more likely to entrapment through the blood-brain barrier, and by not allowing its passage causes an accumulation in the intercellular space of the central nervous system (Hawkins and Davis, 2005). Our results along with that of Kagalou *et al.* (2008a), imply that MCYSTs concentrations in fish tissue does not necessarily dictate its alteration. Thus, the need of combined approaches in future research, in order to gain complete knowledge on the effects of MCYSTs in different fish tissue, is imperative.

Acknowledgements

The authors would like to thank G.N. Antonakopoulos, Medical School, University of Thessaly, for assisting with the tissues histopathological diagnosis and Peter Magee (<http://www.freewebs.com/anglais/englishotherversion.htm>) for language editing.

References

- Ananiadis, C.I. 1959. Limnological study of Lake Karla. Bulletin de l'Institut Océanographique, 1083: 1–19.
- Bartram, J., Burch, M., Falconer, I.R., Jones, G. and Kuiper-Goodman, T. 1999. Situation assessment, planning and management. In: I. Chorus, J. Bartram (Eds), Toxic cyanobacteria in water, Taylor and Francis, London, New York: 179-209.
- Carbis, C.R., Rawlin, G.T., Mitchell, G.F., Anderson, J.W. and McCauley, I. 1996. The histopathology of carp, *Cyprinus carpio* L., exposed to microcystins by gavage, immersion and intraperitoneal administration. Journal of Fish Diseases, 19: 199–207. doi: 10.1111/j.1365-2761.1996.tb00126.x
- Carbis, C.R., Rawlin, G.T., Grant, P., Mitchell, G.F., Anderson, J.W. and McCauley, I. 1997. A study of feral carp, *Cyprinus carpio* L., exposed to Microcystis aeruginosa at Lake Mokoan, Australia, and possible implications for fish health. Journal of Fish Diseases, 20: 81–91. doi: 10.1046/j.1365-2761.1997.d01-111.x
- Carmichael, W.W., Azevedo, S.M.F.O., An, J.S., Molica, R.J., Jochimsen, E.M., Lau, S., Rinehart, K.L., Shaw, G.R. and Eaglesham, G.K. 2001. Human fatalities from cyanobacteria: chemical and biological evidence for cyanotoxins. Environmental Health Perspectives, 109: 663-668. doi: 10.1289/ehp.01109663
- Chatzinikolaou, Y., Ioannou, A. and Lazaridou, M. 2010. Intrabasin spatial approach on pollution load estimation in a large Mediterranean river. Desalination, 250: 118–129. doi: 10.1016/j.desal.2008.12.062.
- Chorus, I. 2001. Cyanotoxin occurrence in freshwaters—a summary of survey results from different countries. In: I. Chorus (Ed.), Cyanotoxins: Occurrence, causes consequences, Springer, Berlin: 75-78.
- Codd, G.A. 1995. Cyanobacterial toxins: occurrence, properties and biological significance. Water Science and Technology, 32(4): 149-156. doi: 10.1016/0273-1223(95)00692-3.
- Codd, G.A., Chorus, I and Burch, M. 1999. Design of monitoring programmes. In: I. Chorus, J. Bartram (Eds), Toxic Cyanobacteria in water: a guide to their public health consequences, monitoring and management, E & FN Spon, London: 313-328.
- Cooley, H.M., Evans, R.E. and Klaverkamp, J.F. 2000. Toxicology of dietary uranium in lake whitefish (*Coregonus clupeaformis*). Aquatic Toxicology, 48: 495–515. doi: 10.1016/S0166-445X(99)00057-0.
- Dietrich, D. and Hoeger, S. 2005. Guidance values for microcystins in water and cyanobacterial supplement products (blue-green algal supplements): a reasonable or misguided approach? Toxicology and Applied Pharmacology, 203: 273–289. doi: 10.1016/j.taap.2004.09.005.
- Dos Santos, A.P.M.E. and Bracarense, A.P.F.R.L. 2008. Hepatotoxicity associated with microcystins. Semina: Ciências Agrárias, 29: 417-430. doi: 10.5433/1679-0359.2008v29n2p417
- Ernst, B. 2008. Investigations of the impact of toxic cyanobacteria on fish. PhD thesis, Constance, Germany: Universität Konstanz. Dissertation, University of Konstanz.
- Fisher, W., Dietrich, D. 2000a. Pathological and biochemical characterization of microcystin-induced hepatopancreas and kidney damage in carp (*Cyprinus carpio*). Toxicology and Applied Pharmacology, 164: 73–81. doi: 10.1006/taap.1999.8861.
- Fischer, W. and Dietrich, D. 2000b. Toxicity of the cyanobacterial cyclic heptapeptide toxins microcystin LR and-RR in early life-stages of the African clawed frog (*Xenopus laevis*). Aquatic Toxicology, 49: 189–198. doi: 10.1016/S0166-445X(99)00079-X.
- Fournie, J. W., Courtney, L.A. 2002. Histopathological evidence of regeneration following hepatotoxic effects of the cyanotoxin Microcystin-LR in the hardhead catfish and Gulf killifish. Journal of Aquatic Animal Health, 14: 273-80. doi: 10.1577/1548-8667(2002)014<0273:HEORFH>2.0.CO;2.
- Hawkins, B.T. and Davis, T.P. 2005. The blood-brain barrier/neurovascular unit in health and disease. Pharmacological Reviews, 57: 173-85. doi: 10.1124/pr.57.2.4.
- Huisman, J., Matthijs, H.C.P. and Visser, P.M. 2005. Harmful cyanobacteria. Springer, Berlin, 243 pp.

- Kagalou, I., Kormas, K.A., Papadimitriou, T., Katsiapi, M., Genitsaris, S. and Moustaka-Gouni, M. 2012. Greece: occurrence, monitoring and risk management of cyanobacteria and cyanotoxins. In: I. Chorus (Ed), Current approaches to cyanotoxin risk assessment, risk management and regulations in different countries, Federal Environmental Agency (Umweltbundesamt), Berlin: 71-78.
- Kagalou, I., Papadimitriou, T., Bacopoulos, V. and Leonardos, I. 2008. Assessment of microcystins in lake water and the omnivorous fish (*Carassius gibelio*, Bloch) in Lake Pamvotis (Greece) containing dense cyanobacterial bloom. Environmental Monitoring and Assessment, 137: 185-195. doi: 10.1007/s10661-007-9739-6.
- Katsiapi, M., Moustaka-Gouni, M., Vardaka, E. and Kormas, K.A. 2013. Different phytoplankton descriptors show asynchronous changes in a shallow urban lake (L. Kastoria, Greece) after sewage diversion. Fundamental and Applied Limnology, 182:219-230. doi: 10.1127/1863-9135/2013/0362
- Kolmakov, V. and Gladyshev, M. 2003. Growth and potential photosynthesis of cyanobacteria are stimulated by viable gut passage in crusian carp. Aquatic Ecology, 37: 237-242. doi: 10.1023/A:1025801326088.
- Kormas, K.A., Gkelis, S., Vardaka, E., Moustaka-Gouni, M. 2011. Morphologic and molecular analysis of bloom-forming *Cyanobacteria* in two eutrophic, shallow Mediterranean lakes. Limnologica, 41: 167-173. doi: 10.1016/j.limno.2010.10.003.
- Kotak, B.J., Semalulu, S., Frytzt, D.L., Prepas, E.E., Hrudey, S.E., Coppock, R.W. 1996. Hepatic and renal pathology of intraperitoneally administered microcystin-LR in rainbow trout (*Oncorhynchus mykiss*). Toxicol, 34: 517-25. doi: 10.1016/0041-0101(96)00009-8.
- Kottelat, M. and Freyhof, J. 2007. Handbook of European freshwater fishes. Publications Kottelat, Berlin, 646 pp.
- Lang, T., Wosniok, W., Barsiene, J., Broeg, K., Kopecka, J. and Parkkonen, J. 2006. Liver histopathology in Baltic flounder (*Platichthys flesus*) as indicator of biological effects of contaminants. Marine Pollution Bulletin, 53: 488-496. doi: 10.1016/j.marpolbul.2005.11.008.
- Li, L., Xie, P., Li, S., Qiu, T., Guo, L. 2007. Sequential ultrastructural and biochemical changes induced in vivo by the hepatotoxic microcystins in liver of the phytoplanktivorous silver carp *Hypophthalmichthys molitrix*. Comparative Biochemistry and Physiology - Part C: Toxicology & Pharmacology, 146: 357-367. doi: 10.1016/j.cbpc.2007.04.008.
- Malbrouck, C., Kestemont, P. 2006. Effects of Microcystins on fish. Environmental Toxicology and Chemistry, 25: 72-86. doi: 10.1897/05-029R.1.
- Mitsoura, A., Kagalou, I., Papaioannou, N., Berillis, P., Mente, E. and Papadimitriou T. 2013. The presence of microcystins in fish *Cyprinus carpio* tissues: an histopathological study. International Aquatic Research, 5: 8. doi:10.1186/2008-6970-5-8
- Moutou, K., Tsikogias, S., Papadimitriou, T. and Kagalou, I. 2012. Oxidative stress in *Cyprinus carpio* to analyze microcystin impact in eutrophic shallow lakes: a preliminary study. Journal of Environmental Monitoring, 14(8): 2195-2203. doi: 10.1039/c2em30129f.
- Nikouli, E., Kormas, K.A., Berillis, P., Karayanni, H. and Moustaka-Gouni, M. 2013. Harmful and parasitic unicellular eukaryotes persist in a shallow lake under reconstruction (L. Karla, Greece). Hydrobiologia, 718: 73-83.
- Nübel, U., Garcia-Pichel, F. and Muyzer, G. 1997. PCR primers to amplify 16S rRNA genes from Cyanobacteria. Applied and Environmental Microbiology, 63: 3327-3332.
- Oikonomou, A., Katsiapi, M., Karayanni, H., Moustaka-Gouni, M. and Kormas, K. 2012. Plankton microorganisms coinciding with two consecutive mass fish kills in a newly reconstructed lake. The Scientific World Journal. doi:10.1100/2012/504135.
- Papadimitriou, T., Kagalou, I., Stalikas, C., Pilidis, G. and Leonardos, I. 2012. Assessment of microcystins distribution and biomagnification in tissues of the aquatic food web compartments from a shallow lake and potential risks for public health. Ecotoxicology, 21: 1155-1166. doi: 10.1007/s10646-012-0870-y.
- Papadimitriou, T., Katsiapi, M., Kormas, K.A., Moustaka-Gouni, M. and Kagalou, I. 2013. Artificially-born "killer" lake: phytoplankton based water quality and microcystin affected fish in a reconstructed lake. Science of the Total Environment, 452-453:116-124. doi: 10.1016/j.scitotenv.2013.02.035.
- Råbergh, C.M.I., Bylund, G. and Eriksson, J.E. 1991. Histopathological effects of microcystin-LR, a cyclic peptide toxin from the cyanobacterium (blue-green algae) *Microcystis aeruginosa*, on common carp (*Cyprinus carpio* L.). Aquatic Toxicology, 20: 131-46. doi: 10.1016/0166-445X(91)90012-X.
- Specziár, A., Tölg, L. and Biró, P. 1997. Feeding strategy and growth of cyprinids in the littoral zone of Lake Balaton. Journal of Fish Biology, 51: 1109-1124. doi: 10.1006/jfbi.1997.0514.
- Specziár, A., Biro, P. and Tolg, L. 1998. Feeding and competition of five cyprinid fishes in different habitats of the Lake Balaton littoral zone, Hungary. Italian Journal of Zoology, 65: 331-336. doi: 10.1080/11250009809386842.
- Vardaka, E., Moustaka-Gouni, M., Cook, C.M. and Lanaras, T. 2005. Cyanobacterial blooms and water quality in Greek waterbodies. Journal of Applied Phycology, 17: 391-401. doi: 10.1007/s10811-005-8700-8.
- Welker, M., Chorus, I. and Fastner, J. 2004. Occurrence of cyanobacterial toxins (microcystins) in surface waters of rural Bangladesh- pilot study. In W.H.O. Report, Bangladesh: 1-24.
- WHO 1998. Blue-green algae in inland waters: Assessment and control of risks to public health. WHO Document, Annex G.
- Xie, L.Q., Xie, P., Ozawa, K., Honma, T., Yokoyama, A., and Park, H.D. 2004. Dynamics of microcystins-LR and -RR in the phytoplanktivorous silver carp in a sub-chronic toxicity experiment. Environmental Pollution, 127: 431-439. doi: 10.1016/j.envpol.2003.08.011.
- Zurawell, R.W., Chen, H., Burke, J.M. and Prepas, B.R. 2005. Hepatotoxic cyanobacteria: A review of the biological importance of microcystins in freshwater environment. Journal of Toxicology and Environmental Health, 8(B): 1-37. doi: 10.1080/10937400590889412.