

First Case of Morphological Abnormality in Common Angel Sharks *Squatina squatina* (Chondrichthyes: Squatinidae), from the Canary Islands.

Alejandro Escánez Pérez^{1,4*}, Sergio Moreno Borges², Felipe Ravina Olivares³, Sandra J. Raredon⁵

¹ Vigo University, Experimental Building Sciences, Biology Faculty, Department of Ecology and Animal Biology, PC 36310, Vigo, Pontevedra, Spain

² Soil Sciences and Geology. La Laguna University, Department of Animal Biology, La Laguna, Santa Cruz de Tenerife, Spain.

³ Species from Canary Organization. Santa Cruz de Tenerife, Spain.

⁴ Tonina Association, La Laguna, Santa Cruz de Tenerife, Spain.

⁵ Smithsonian Institution, Division of Fishes – MRC 534, Museum Support Center, 4210 Silver Hill Road, Suitland, MD 20746.

Tel.: +34 646752466

Email: aescanez@msn.com

Abstract

The first cases of spinal abnormalities for the common angel shark *Squatina squatina* in the Canary Islands (Spain), are reported. Two specimens, a juvenile and an adult female with 21° and 42° of scoliosis were recorded in Tenerife and Gran Canaria islands, respectively. Possible causes are discussed.

Keywords: angel shark, *Squatina squatina*, deformity, scoliosis.

Introduction

Diverse morphological deformities have been described in elasmobranchs. These abnormalities include skeletal deformities, as lateral spinal curvature (scoliosis), humpback curvature (kyphosis), axial spinal curvature (lordosis), vertebral fusion, deformed chondrocranium, missing fins, additional fins, abnormal caudal fins, deformed snout, among others (Hoenig & Walsh, 1983; Heupel, Simpfendorfer & Bennett, 1999; Moore, 2015).

While these abnormalities have been frequently reported in captive sharks, few records have been reported in free-swimming specimens. The causes of many of these deformities are unknown; however, some authors have suggested dietary nutritional imbalance (e.g. lack of vitamin c), genetic factors, parasites, ambient factors, diverse kinds of disease, traumatic injuries or asymmetrical stress in aquaria specimens (Heupel et al., 1999; Preziosi et al., 2006; Huber, Neveu, Stinson, Anderson & Berzins, 2013; Tate, Anderson, Huber & Berzins, 2013; Moore, 2015).

The common angel shark *Squatina squatina* (Linnaeus, 1758), is a dorsoventrally flattened shark that inhabits sandy seabeds close to the littoral zone of 150 m depth (Golani et al., 2006). This shark has been assessed as critically endangered by the International Union for Conservation of Nature (IUCN) (Ferretti et al., 2015) and

belongs to the Squatinidae family, the second most endangered shark family in the world (Dulvy et al., 2014). The common angel shark (*S. squatina*) historically was common over large areas of the North-East Atlantic, from Norway, Sweden and the Shetland Islands to Morocco, West Sahara, the Canary Islands and the Mediterranean and Black Seas. Intensive demersal fishing pressure throughout its range has resulted in significant declines of its populations and almost are extinct in most of its original range (Ferretti et al., 2015). In a recent review on the distribution of large sharks in eastern Mediterranean, Kabasakal, Karhan and Sakman (2017) emphasized that individual contribution of *S. squatina* specimens to bycaught large sharks by commercial fishermen was $\leq 2\%$ of the total catch, between 1990 and August 2015.

Currently, the Canary Islands angel shark population is considered the most abundant, being frequent its encounters with divers in all islands, through the year (Escánez, Crespo, Rodríguez, Oñate & Marrero, 2016). In contrast, common angel sharks reports from other areas have been dramatically decreasing in the last middle century. For example, in the Mediterranean only two specimens have been reported since 1985 to 2015 in the Sicilian coast, while only eight specimens have been reported from the Turkish waters since 1990 to 2015 (Kabasakal et al., 2017). This same pattern has been observed for other Mediterranean and North Atlantic regions (Roger & Ellis, 2000; Kabasakal & Kabasakal, 2014; Cavallaro, Danze, Ammendolia & Navarra, 2015; Akyol, Ünal & Capapé, 2015).

Among the 13 shark species with morphological abnormalities recorded worldwide, the pacific angel shark *Squatina californica* Ayres, 1859 is the only species in the Squatinidae family where albinism and synophthalmia have been described in two embryos in the Gulf of Mexico (Escobar-Sánchez, Moreno-Sánchez, Aguilar-Cruz & Abitia-Cárdenas, 2014). This brief communication describes two cases of morphological deformity observed for first time in free-swimming *S. squatina* in two islands of the Canary archipelago, and their potential causes are discussed.

Materials and Methods

Due the status of Critically Endangered species based in Red List of the IUCN, the specimens of this study no were sacrificed or subjected to any procedure that caused pain, suffering, distress or lasting harm, in consonance with Spanish legislation about animal welfare for scientific purposes.

In November 2015, during a nocturnal survey at Las Teresitas Beach in Tenerife, Spain ($28^{\circ} 30'25.30''N$, $16^{\circ}11.00'15''W$), a young female *S. squatina* that showed a skeletal deformity was captured using a hand net at 1m depth. The specimen was placed in a water tray to be measured and photographed, before its release. The second case was reported in November 2016. An adult female was observed during scuba-diving in Caleta de Abajo, Gran Canaria, Spain ($28^{\circ}9'45.99''N$, $15^{\circ}40'50.26''W$) at 10 meters depth. The occurrence was video-recorded. The total length L_T of the animal was visually estimated. The images were processed and analysed using ImageJ software and GIMP 2. The angles of spinal curvature were estimated by tracing a perpendicular across the middle of the intersection between eyes (sagittal plane) and the rotation from the resulting perpendicular to the current position of the animal (Figure 1).

In order to complement the photograph, we included one X-ray images from one *S. squatina* belonging to the collection of the Division of Fishes of Smithsonian Institution (Figure 1c).

Results

The specimen captured on November 2015 was an immature female of 24 cm L_T (Fig. 1a). It showed a lateral spinal curvature (scoliosis) of 21° and an approximate humpback curvature of 25° (kyphosis). The second individual was a ~ 120 cm L_T adult female (Figure 1b) which showed another case of scoliosis with a curvature of 42° . Both animals showed the spinal curvature approximately at level of the middle of pectoral fins (Figure 1). This deformity apparently did not affect the swimming capacity in neither of them. However, the left branchial opening in the adult female (b) had severe distension, enlarging its normal aperture. The radiographed specimen from Smithsonian's fish collection was a juvenile of 23 cm L_T captured at Italy with reference code in the collection USNM 28457 (Figure 1c). It showed 45 monospondylous vertebrae with the transition to diplospondylous vertebrae placed posterior to the pelvic girdle, and a total number of 120 vertebrae. The comparison of the deformed animals with the X-ray image suggested that in both cases the injuries occur between vertebrae 10 to 20.

Discussion

Spinal scoliosis has been reported in diverse shark species, most in pelagic sharks that depend on their swimming abilities to catch prey. Many cases have reported abnormal curvatures in the spinal or caudal fin without causing a negative impact on their predatory activity (Moore, 2015; Afonso et al., 2016). In the same manner, the deformity described here for *S. squatina* seems not to significantly affect its hunting capacity, which consists in burying itself to catch its preys by ambush. Using this hunting method, swimming agility is perhaps less essential. This deformity is not apparently lethal given that the second case was an adult female, but it could negatively affect mating.

We suggest that the physical injuries were most probably caused by human interactions, given the constant interference in the coastal areas where juvenile angel sharks inhabit. For example, bites to bathers that stepped on buried new born or juveniles individuals have been frequently reported in nursery areas (Escáñez et al., 2016). In the same way, accidental fishing of young specimens and their careless handling during release process could produce injuries that result in skeletal deformities. However, we cannot rule out other potential causes speculated by different authors such intraspecific aggressions, diseases, genetic factors or environmental stressors. This latter case, e.g. higher temperature and salinity values have been highlighted as potential physiological stressors which cause morphological abnormalities in fish development (Ottesen & Bolla, 1998; Pimentel et al., 2014; Moore, 2015;). Furthermore, marine contaminants like polycyclic aromatic and aliphatic hydrocarbons can produce biological disorders and DNA damage in fishes including sharks. These contaminants can be transferred from the mother to unborn individuals, potentially producing abnormal embryos in sharks (Al-Hassan, Afzal, Rao & Fayad, 2000; Gelsleichter & Walker, 2010).

The frequency of this spinal deformity in *S. squatina* appears relatively low (0.5%). Only one abnormal individual has been sighted among 213 juveniles at Las Teresitas beach during the years 2014 and 2015 (Escáñez et al., 2016). This frequency is similar to that reported for *Hemiscyllium ocellatum* (Bonnaterre, 1788) (0.58%) (Heupel et al., 1999) but lower than *Carcharhinus limbatus* (Müller & Henle, 1839) (7.7%) (Moore, 2015), *Carcharhinus leucas* (Müller & Henle, 1839) (11%) (Afonso et al., 2016) or *Carcharias taurus* Rafinesque, 1810 specimens from aquaria (35%) (Huber et al., 2013). Further research is required to determine the causes of these deformities and their impact at population level within the last stronghold of this endangered shark, the Canary Islands.



Acknowledgements

This paper is part of the Asociación Tonina project, Bioecological Study of Angel Shark Nursery Areas from Tenerife Island, 2016CP19, which is supported by funding from the CajaCanarias Foundation. All fishes were captured and release under Animal ethics permit N°: 408/2014 approved by the Department of Agriculture, Livestock, Fishing and Water, of the Canary Islands Government. Thanks to Smithsonian Institution for granting the X-ray images of both individuals of *S. squatina* from its collection. Thanks to Jacobo Marrero, Ana Crespo (Asociación Tonina), Omar Álvarez and Rodrigo Riera (Centro de Investigaciones Medioambientales del Atlántico) for helping during the field survey. Thanks to Charlotte Mykura for the English revision of the manuscript.

References

- Afonso, A. S., Niella, Y. V., Cavalcanti, E., Andrade, M. B., Afonso, J. S., Pinto, P. S. & Hazin, F. H. V. (2016). Spinal deformities in free-ranging bull sharks, *Carcharhinus leucas* (Müller and Henle, 1839), from the western South Atlantic Ocean. *Journal of Applied Ichthyology*, 32, 1217-1220. <https://dx.doi.org/10.1111/jai.13125>
- Akyol, O., Ünal, V. & Capapé, C. (2015). Occurrence and Biological Observations on Angel shark *Squatina squatina* (Chondrichthyes: Squatinidae) from the Turkish Waters (Eastern Mediterranean). *Turkish Journal of Fisheries and Aquatic Sciences*, 15, 931-935. https://doi.org/10.4194/1303-2712-v15_4_17
- Al-Hassan, J. M., Afzal, M., Rao, C. V. N. & Fayad, S. (2000). Petroleum hydrocarbon pollution in sharks in the Arabian Gulf. *Bulletin of Environmental Contamination and Toxicology*, 65, 391-398. <https://doi.org/10.1007/s0012800140>
- Cavallaro, M., Danze, A., Ammendolia, G. & Navarra, E. (2015). Finding of a rare *Squatina squatina* (Linnaeus, 1758) (Chondrichthyes: Squatinidae) along the Tyrrhenian coast of the Strait of Messina and its maintenance in an aquarium. *Marine Biodiversity Records*, 8, e44: 1-4. <https://doi.org/10.1017/S1755267215000226>
- Dulvy, N.K., Fowler, S.L., Musick, J.A., Cavanagh, R.D., Kyne, P.M., Harrison, L.R., ... Francis, M.P. (2014). Extinction risk and conservation of the world's sharks and rays. *Elife*, 3, e00590. <https://doi.org/10.7554/eLife.00590.001>
- Escáñez, A., Crespo, A., Rodríguez, S., Oñate, M. & Marrero, J. (2016). Estudio del primer área de cría del Angelote (*Squatina squatina*) descubierta en Canarias. *Chronica naturae*, 6, 50-62.
- Escobar-Sánchez, O., Moreno-Sánchez, X. G., Aguilar-Cruz, C. A. & Abitia-Cárdenas, L. A. (2014). First case of synophthalmia and albinism in the Pacific angel shark *Squatina californica*. *Journal of Fish Biology*, 85, 494-501. <https://doi.org/10.1111/jfb.12412>
- Ferretti, F., Morey, G., Serena, F., Mancusi, C., Fowler, S.L., Dipper, F. & Ellis, J. (2015). *Squatina squatina*. The IUCN Red List of Threatened Species 2015. <http://dx.doi.org/10.2305/IUCN.UK.2015-1.RLTS.T39332A48933059.en>
- Gelsleichter, J. & Walker, C. J. (2010). Chapter 12. Pollutant exposure and effects in sharks and their relatives. In J.C., Carrier, J.A., Musick & M.R., Heithaus (Eds.), *Sharks and their Relatives, Volume II*. Boca Raton, FL: CRC Press. <https://doi.org/10.1201/9781420080483-c12>
- Golani, D., Öztürk, B. & Başusta, N. (2006). *Fishes Of The Eastern Mediterranean*. Turkish marine research foundation. Publication number: 24. Beykoz, Istanbul.
- Heupel, M. R., Simpfendorfer, C. A., & Bennett, M. B. (1999). Skeletal deformities in elasmobranchs from Australian waters. *Journal of Fish Biology*, 54, 1111-1115. <https://doi.org/10.1111/j.1095-8649.1999.tb00861.x>
- Hoenig, J. M., & Walsh, A. H. (1983). Skeletal lesion and deformities in large sharks. *Journal of Wildlife Diseases*, 19, 27-33. <https://doi.org/10.7589/0090-3558-19.1.27>
- Huber, D. R., Neveu, D. E., Stinson, C. M., Anderson, P. A. & Berzins, I. K. (2013). Mechanical properties of sand tiger shark (*Carcharias taurus*) vertebrae in relation to spinal deformity. *Journal of Experimental Biology*, 216, 4256-4263. <https://doi.org/10.1242/jeb.085753>
- Kabasakal, H. & Kabasakal, Ö. (2014). Status of angelshark, *Squatina squatina* (elasmobranchii: squatiniformes: squatinidae) in the Sea of Marmara. *Annales series historia naturalis*, 24, 41-46.
- Kabasakal, H., Karhan, S. Ü. & Sakınan, S. (2017). Review of the distribution of large sharks in the seas of Turkey (eastern Mediterranean). *Cahiers de Biologie Marine*, 58, 219-228. <https://doi.org/10.21411/CBM.A.96D9F948>
- Moore, A. B. M. (2015). Morphological abnormalities in elasmobranchs. *Journal of Fish Biology*, 87, 465-471. <https://doi.org/10.1111/jfb.12680>
- Ottesen, O. H. & Bolla, S. (1998). Combined effects of temperature and salinity on development and survival of Atlantic halibut larvae. *Aquaculture International*, 6, 103-120. <https://doi.org/10.1023/A:1009234122861>
- Pimentel, M. S., Faleiro, F., Dionísio, G., Repolho, T., Pousão-Ferreira, P., Machado, J., & Rosa, R. (2014). Defective skeletogenesis and oversized otoliths in fish early stages in a changing ocean. *Journal of Experimental Biology*, 217, 2062-2070. <https://doi.org/10.1242/jeb.092635>
- Preziosi, R., Gridelli, S., Borghetti, P., Diana, A., Parmeggiani, A., Fioravanti, M. L., ... Berzins, I. (2006). Spinal deformity in a sandtiger shark, *Carcharias taurus* Rafinesque: a clinical-pathological study. *Journal of Fish Diseases*, 29, 49-60. <https://doi.org/10.1111/j.1365-2761.2005.00684.x>

- Rogers, S. I. & Ellis, J. R. (2000). Changes in the demersal fish assemblages of British coastal waters during the 20th century. *ICES Journal of Marine Science* 57, 866-881. <https://doi.org/10.1006/jmsc.2000.0574>
- Tate, E. E., Anderson, P. A., Huber, D. R. & Berzins, I. K. (2013). Correlations of swimming patterns with spinal deformities in the sand tiger shark, *Carcharias taurus*. *International Journal of Comparative Psychology*, 26, 75-82.

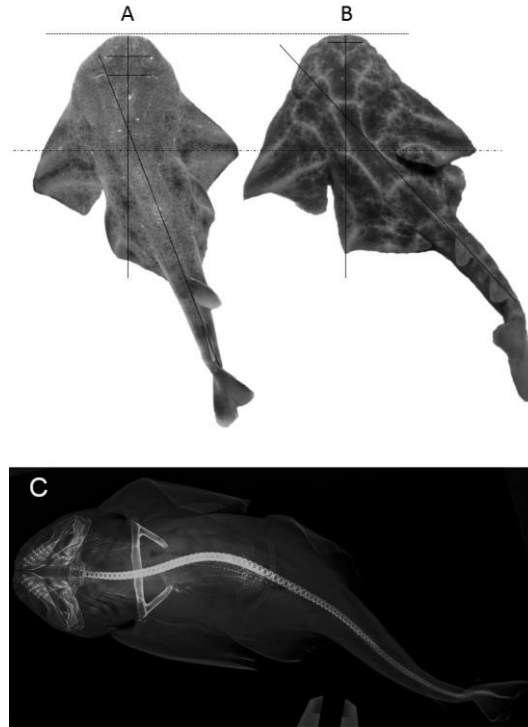


Figure 1.