



## Effect of Different Dietary Inclusion Levels of Melon Seed (*Citrullus lanatus*) Peel on Growth, Haematology and Histology of *Orochromis niloticus* Juvenile

S. C. Iheanacho<sup>1,\*</sup>, N. Ikwo<sup>2</sup>, N. O. Igweze<sup>2</sup>, C. Chukwuidha<sup>2</sup>, E. O. Ogueji<sup>1</sup>, R. Onyeneke<sup>3</sup>

<sup>1</sup> Department of Fisheries and Aquaculture, Federal University Ndufu Alike Ikwo, Ebonyi State, Nigeria.

<sup>2</sup> Department of Fisheries and Aquaculture, Ebonyi State University Abakaliki, Ebonyi State, Nigeria.

<sup>3</sup> Department of Agriculture, Federal University Ndufu Alike Ikwo, Ebonyi State, Nigeria.

\* Corresponding Author: Tel.: +234 8063279905;  
E-mail: iheanacho.stanley@yahoo.com

Received 22 April 2017  
Accepted 11 July 2017

### Abstract

High demand and expensive nature of conventional basal feed stuffs used in fish diet has led to search for alternative and cheap basal feed sources. This study was carried out to evaluate the effect of melon seed peel on growth, haematology and histology of *Orochromis niloticus*. 150 *Orochromis niloticus* juveniles (25.24±1.72g) were assigned to varying dietary levels of melon seed peel (MSP) namely 0, 25, 50, 75 and 100% as diet treatments. Each treatment had ten fish per tank and was triplicated. Fish were fed twice daily at 5% body weight for 56 days. Fish were weighed at the end of the experiment. Blood samples from each treatment were collected for haematological examination. Histology of fish intestine was examined. Data obtained were subjected to analysis of variance (ANOVA). Significant differences ( $p < 0.05$ ) were observed in all the growth and haematological parameters. Treatment 5 had the best growth performance compared to other treatments and control. PCV and Hb values were found to be highest in treatment 5 followed by control. Histological examination revealed that 100% (treatment 5) dietary inclusion level of MSP had no deleterious effect on the fish while 25% dietary inclusion showed mild changes in the structure of the villi found in the epithelial mucosa of fish intestine. 100% dietary inclusion level of MSP is recommended in the diet of *Orochromis niloticus*.

**Keywords:** Effect, melon-Seed-peel, growth, haematology, Histology, *Orochromis niloticus*.

### Introduction

Aquaculture is the largest animal food production sector (FAO, 2010). Orire and Ricketts (2013) opined that the success of aquaculture largely depend on the capability of fish farmers to formulate nutritionally balanced diets that will meet the nutrient requirements of their cultured species at lower cost. Production of quality fish feed is considered a critical factor in aquaculture as it ensures growth efficiency, quality flesh and feed utilization (Tsevis & Azzaydi, 2000). Nutrient requirements of fish species differs, hence it is necessary for fish farmers to have the knowledge of the nutritional history of their preferred aquaculture species as to formulate a nutritionally balanced diets that will ensure optimal growth (Steven & Louis, 2002). The expensive nature of most conventional feed stuffs is the major challenge faced by local fish farmers (Abowei & Ekubo, 2011). Ogunlande (2007) reported that high demand for the conventional feed ingredients by other sectors and also for human consumption contributed to expensive and competitive nature of these conventional feed ingredients. Gabriel, Akinrotimi, Bekibebe, Onunkwo, and Anyanwu (2007) reported

that fish feed account for 50-60% of aquaculture production, hence has necessitated the search for cheap and locally available feed stuffs that can serve as alternative energy feed for fish. The paradigm shift is aimed at reducing production cost without compromising feed quality (Houlihan, Bouiard, & Jobling, 2001).

Residues such as husk, shell, back etc., gotten from most agricultural products have been identified as waste and constitute environmental hazards. Orire and Ricketts (2013) reported that these wastes could be utilised effectively as feed ingredients for fish and livestock feeds. Most of these crop residues have been found to contain good amount of fibre, ash, lipid and protein (Obi, Kolo & Orire, 2011; Orire, & Ricketts, 2013). Unconventional feed stuffs and agricultural by-products can serve as substitute for expensive conventional feed stuffs in fish diet (Falaye, 1992). Melon (*Citrullus lanatus*) is a plant species which originated from Africa and wildly cultivated as fruit (Chomicki & Renner, 2014). Melon seed contains mineral nutrients, oil and substantial amount of protein (ranging from 18-28%) (Abaelu, Makinde, & Akinrimisi, 1979; Obi, Kolo, & Orire, 2011). Melon seed peel is common and usually seen

as agricultural waste (Obi, Kolo, & Orire, 2011).

Nile tilapia (*Oreochromis niloticus*) is the second largest cultured species in Nigeria and is widely cultivated in earthen/concrete ponds, cages and reservoirs in Nigeria (Fagbenro, 2004). Nile tilapia species are suitable aquaculture species and require less technology farming systems due to their rapid growth rate, proficient utilization of natural aquatic foods, tendency to consume a variety of supplementary feeds, high reproductive proliferation even in captivity, omnivorous food habits, and tolerance to wide ranges of environmental conditions (Fagbenro, 1987; El-Sayed, 2006; Nguyen, Davis, & Saoud, 2009).

In a nutshell, this study is aimed at accessing the effect of melon seed peel as alternative dietary energy source on the growth, haematology and histology of *Oreochromis niloticus*

## Materials and Methods

### Experimental Fish

One hundred and fifty (150) *Oreochromis niloticus* juveniles were procured from a private fish farm in Abakaliki and transported in a 50litre gallon filled with water to the Department of Fisheries and Aquaculture wet laboratory, Ebonyi State University within 30-40 minutes. The fish were acclimated in a tarpaulin tank (4x2x1m) for two weeks and were fed commercial fish feed (coppens) throughout the 2 weeks acclimation period.

### Collection and Processing of Melon Seed Peel

Melon seed peels were collected from the melon milling house at Abakpa market where it was heaped. The peels were sundried for 3 days. Dirt were sieved out using a hand sieve. The peels were ground into powdered form with the aid of a grinding machine and stored in an airtight container. Proximate composition of melon seed peel were determined following the formula of A.O.A.C (2000).

### Experimental Diets

Five (5) iso-nitrogenous diets were formulated to yield 30% crude protein. Melon seed peel (MSP) was included in the diets as alternative energy source to replace maize at different inclusion levels. The different inclusion levels of Melon seed Peel were 25%, 50%, 75% and 100% . The control diet had 0% inclusion of Melon seed peel. Other feed ingredients used in the diet formulation includes soy bean meal (SBM), groundnut cake (GNC), yellow maize (YM), fish meal (FM), vitamin/mineral premix, starch, palm oil and salt (Table 1). Pearson square method was used in feed formulation. Samples of the experimental diets were sent to the laboratory for proximate analysis as described by A.O.A.C (2000).

## Experimental Design

One hundred and fifty fish (150) (initial weight  $25.24 \pm 1.72g$ ) were randomly distributed to fifteen aquarium plastic tanks (1x1x1m) at ten fish per treatment. Each tank contained 20 litres of water. Experimental diets were randomly assigned using completely randomized design to triplicate tanks. The fish were fed 5% body weight per day in two portions (by 9.00 hours and 16.00 hours) for 56 days. Quantity of feed was adjusted forth nightly after batch-weighing of experimental fish. Water in the tanks was removed partly by siphoning and replaced with fresh water every three days to avoid fouling resulting from faeces and uneaten food. Water temperature, dissolved oxygen and pH in the experimental tanks were monitored and measured two times daily (morning (6am) and evening 6pm) using mercury glass thermometer and water testing kits ( PRO-LAB™ Water Quality Test Kit, U.S.A). Temperature, pH and dissolved oxygen were maintained at  $26.16 \pm 0.01$  °C,  $6.97 \pm 0.03$  and  $6.98 \pm 0.11mg L^{-1}$  respectively.

### Growth Parameters

Weight measurement of the fish was obtained at the end of the experiment and the following growth parameters were determined according to the formula of Iheanacho *et al.* (2017) and Sogbesan and Ugwumba (2008).

$$\text{Mean Weight Gain} = \text{Final weight} - \text{Initial weight}$$

### Specific Growth Rate (SGR)

$$\text{SGR} = \frac{(\text{Ln Mean final weight} - \text{Ln Mean initial weight}) \times 100}{\text{Time (days)}}$$

Ln = natural logarithm

### Food Conversion Ratio

$$\text{This is expressed as FCR} = \frac{\text{Weight of food fed (Dry gram weight)}}{\text{Weight gain of fish (Wet gram weight)}}$$

### Protein Efficiency Ratio (PER)

$$\text{This measure the protein efficiency ratio PER} = \frac{\text{Weight gain of fish}}{\text{Protein fed}}$$

$$\text{Survival Rate (\%)} = \frac{\text{Total number of survival} \times 100}{\text{total number of fish stocked}}$$

### Haematological Analysis

Two fish per tank were sampled for blood collection at the end of the experiment. Blood was collected from the caudal vein into an EDTA litium tubes. The blood was analyzed to determine the packed cell value (PCV) with micro haematocrit using heparnized capillary tube (25mm) while Red blood

**Table 1.** Experimental diet formulation (%)

Ingredients	Control(0%MSP)	D1(25% )	D2(50%)	D3(75%)	D4(100%)
FM	26.00	26.00	26.00	26.00	26.00
GNC	19.10	19.10	19.10	19.10	19.10
SBM	18.58	18.58	18.58	18.58	18.58
YM	32.47	28.38	24.39	20.35	16.31
MSP	-----	4.09	8.08	12.12	16.16
Lysine	0.48	0.48	0.48	0.48	0.48
Methionine	0.48	0.48	0.48	0.48	0.48
Vit. premix	0.48	0.48	0.48	0.48	0.48
Salt	0.81	0.81	0.81	0.81	0.81
Palm oil	0.81	0.81	0.81	0.81	0.81
Starch	0.81	0.81	0.81	0.81	0.81
Total	100	100	100	100	100

cell (RBC), white blood cell (WBC) counts and Haemoglobin (Hb) concentration were determined as described by Dacie and Lewis (2011).

### Histological Analysis

Histological study was carried out at the histology and histopathology laboratory of the Department of Anatomy, Ebonyi State University Abakaliki, according to the procedure described by Belelander and Ramaley (1979). One fish from each of the tank were randomly selected the end of the experiment. Fishes were dissected and pieces of tissue samples from the stomach lining were excised, rinsed in physiological saline and immediately fixed in Bouin's fluid before embedding in paraffin wax of melting point 56 °C. Section were cut using microtome and sizes of sections averaged 10 µm. Sections were left stained in haemoxylin for 10minutes and later transferred to acid alcohol for 20 seconds. Sections were immersed in container half filled with tap water and left for 10 minutes to remove the acid alcohol and transferred into 10 % aqueous eosin for 2 minutes, while excess eosin was washed in running tap water. Dehydration of sections with 70 %, 90 % and absolute alcohol was carried out. Finally sections were mounted in DPX chemical and dried at room temperature. Sections were viewed under binocular microscope after injecting 95 % ethanol between the glass slides for better light refraction (Ezenwa & Kusemiju, 1985). An ocular micrometer was mounted with the right eye piece, with a conversion factor of 0.006mm for each unit. This conversion factor was calculated from the graduated and absolute units of stage micrometer. The photomicrographs of the final stage of the sections were taken.

### Statistical Analysis

Data obtained from each parameter after the experiment were subjected to one-way analysis of variance (ANOVA), using SPSS (Statistical package for Social Science 2006, version 22). Duncan multiple

range test (DMRT) was used to compare the differences between means at ( $P < 0.05$ ). Data were presented as mean  $\pm$  SE.

### Results

Proximate composition of feed ingredients is presented in table 2. Fish meal had the highest values for crude protein (72.00), fat (11.17) and ash (14.80) followed by groundnut cake (GNC) (45.00, 5.94 and 13.80) respectively. Melon seed peel (MSP) contains 14.88 crude protein and had the highest value for crude fibre (5.67). Maize had lowest values for crude protein (10.00), fat (2.69) and ash (1.40).

Proximate composition of experimental diets is presented in table 3. Moisture content was highest in diet 4 (6.08) while diet 3 had the lowest moisture content (5.37). Diet 3 had the highest ash percentage (11.35%) followed by diet 5 (11.33%), while the lowest value for ash was seen in diet 1(11.24%). Diet 3 had the highest value for crude protein (44.28%) followed by diet 1 while diet 2 had the lowest crude protein percentage (43.97%).

Result on growth performances of *Oreochromis niloticus* fed with different dietary inclusions of melon shell peel are presented in table 4. Significant difference ( $p < 0.05$ ) was observed among diet treatments. Highest values for all the growth parameters were seen in fish fed with diet 5 (100%MSP) followed by the fish fed with diet 4 (75%MSP) when compared to the control. Lowest values for final body weight and weight gain were observed in treatment 2.

Result on haematological study is presented in table 5. There was significant difference ( $p < 0.05$ ) among dietary treatments compared to the control. Values for PCV and Haemoglobin (Hb) was highest in treatment 5 followed by treatment 1 (control) while treatment 3 had the lowest values for the same parameters. Significant increase ( $p < 0.05$ ) in RBC was observed in treatment 4 compared other treatments and the control. Treatment 3 had the highest value for WBC while treatment 4 had the lowest WBC value.

Results on histological analysis of intestinal wall

**Table 2.** Proximate composition of feed ingredients (%)

Ingredient	Crude protein	Fat	Crude fibre	Ash	Moisture
Soybean Meal	44.00	2.59	5.00	4.60	5.70
Fish Meal	72.00	11.17	1.31	14.80	9.02
Yellow maize	10.00	2.69	1.40	1.40	8.52
GNC	45.00	5.94	4.31	13.80	6.31
MSP	14.88	3.16	5.67	6.98	7.16

GNC = ground nut cake, MSP= melon seed peel.

**Table 3.** Proximate composition of Experimental Diets

Parameters	TD <sub>1</sub> (0% MSP)	TD <sub>2</sub> (25% MSP)	TD <sub>3</sub> (50% MSP)	TD <sub>4</sub> (75% MSP)	TD <sub>5</sub> (100% MSP)
Moisture (%)	5.46	5.48	5.37	6.08	6.07
Crude Fat (%)	4.29	4.25	4.37	4.16	4.15
Ash (%)	11.24	10.73	11.35	10.83	11.33
Crude Fibre (%)	2.66	2.71	2.57	2.65	2.71
Crude Protein (%)	44.27	43.97	44.28	44.15	44.18
NFE (%)	32.08	32.86	32.06	32.10	31.56

NFE - Nitrogen Free Extract = (100 – moisture + crude protein + ash + crude fat).

of *O. niloticus* fed different dietary inclusion levels of melon seed peel are presented in Figure 1 to 5. Plate 1 (control) indicates normal epithelium of mucosal fold in the intestine. The villi (finger-like projections) attached to the intestinal wall show normal shape. Plate 2 (25% MSP) revealed changes in shape and erosion of the villi. The villi were found to be structured but unseparated in plate 3 (50% MSP). Plate 4 (75% MSP) indicates normal structure with mild erosion of villi. Plate 5 (100% MSP) also indicates normal and pronounced villi structure. The individual villus is well separated from each other.

## Discussion

Melon seed peel has being reported to be a good dietary energy source in the diet of Nile tilapia (Orire & Ricketts, 2013). The present study is aimed at ascertaining the effects of different dietary inclusion levels of melon seed peel on the growth performance, haematology and histology of *Orochromis niloticus*. Diet 5 (100% MSP) significantly increased ( $p < 0.05$ ) the growth of the fish with regards to final weight, weight gain, protein efficiency ratio and specific growth rate, compared to other diet treatments and the control. This may be due to the availability of nutrients and sufficient energy needed for metabolic activities and growth. However, diet 4 (75% MSP) expressed second best in terms of growth performance followed by diet 3 (50% MSP), although there was no significant difference ( $p > 0.05$ ) in their growth indices. This implies that MSP as energy source improved the growth of the fish compared to the control. Orire and Ricketts (2013) reported better good performance when *O. niloticus* were fed MSP supplemented diet. The study confirms the work of Nwana, Falaye, Olarewaju, and Oludapol (2009), who reported that

the use of potato peel as dietary carbohydrate source improved the growth performance of *O. niloticus*.

Haematological indices are important parameters for evaluating physiological and pathological changes in fish (Erhunmwunse & Ainerua, 2013). Haematological study provides reliable information on health status, metabolic disorders and chronic stress status before and after clinic examination of specimens (Bahmani, Kazem, & Donskaya, 2001). Haematological assessment of *O. niloticus* fed with different dietary inclusion levels of melon seed peel have been reported in the current study (Table 5). The findings of the current study revealed that diet 5 (100% MSP) had the highest values for PCV and Hb followed by the control, while diet 4 (75% MSP) significantly increased RBC compared to other diets. This implies that MSP added to the diet of *O. niloticus* at increased dietary inclusion levels had no negative consequence on blood parameters. Ikwor and Nwapka (2016) reported an increase in PCV, Hb, RBC and WBC values when *C. gariepinus* fingerlings were fed different dietary levels of melon peel diet. Agbebi *et al.* (2013) reported a significant increase in RBC and PLT when agro-waste replaced maize as carbohydrate source in *C. gariepinus* diet.

Histological examination revealed mild changes ( $p < 0.05$ ) in the intestines of *Orochromis niloticus* fed varying dietary inclusion levels of melon seed peel compared to control. Normal epithelium of mucosal fold in the intestine of the fish was observed in the control (plate 1). It is obvious that villi (tentacle-like structures) are normal and individual villus remains separated (plate 1). Intestinal villi are absorptive area of digested food (Haques, Pal, Mukherjee, & Ghosh, 2012). Mucosal folds are also observed to be structurally intact. Cellular structure was observed to be normal as well. Degenerative

**Table 4.** Growth response of *O. niloticus* juvenile fed various levels of melon seed peel based diets

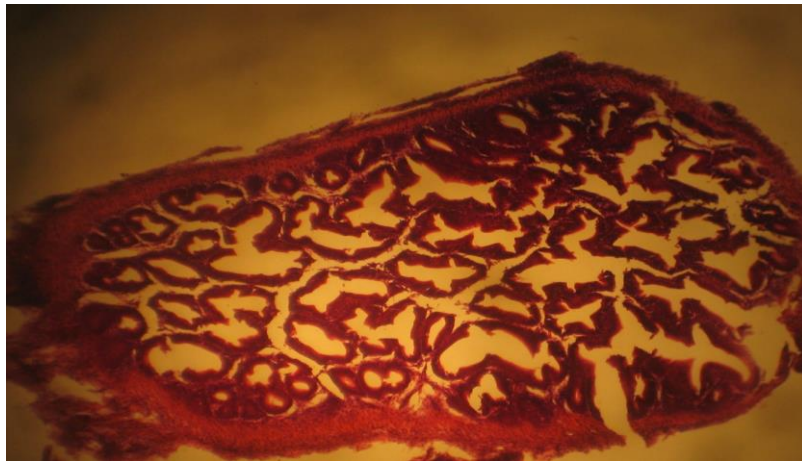
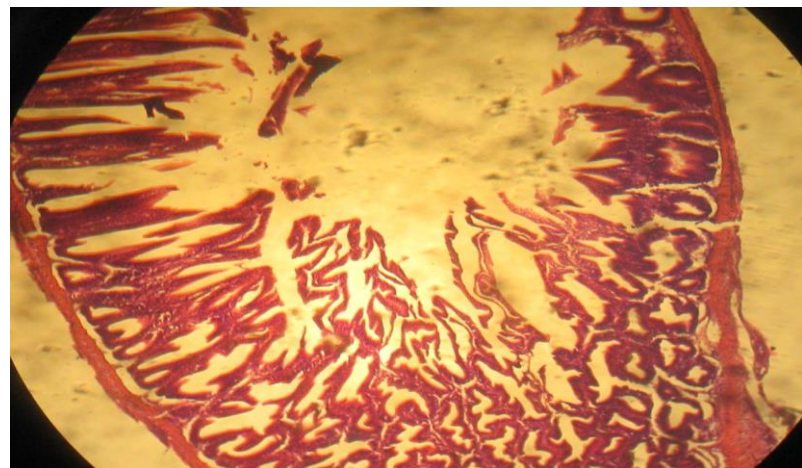
Parameters	TD <sub>1</sub> (0%MSP)	TD <sub>2</sub> (25%MSP)	TD <sub>3</sub> (50%MSP)	TD <sub>4</sub> (75%MSP )	TD <sub>5</sub> (100%MS P)
Initial mean body weight(g)	2 25.73±1.99 <sup>a</sup>	25.64±0.73 <sup>a</sup>	25.56±1.76 <sup>a</sup>	25.24±1.72 <sup>a</sup>	<b>25.02±1.34<sup>a</sup></b>
Final mean body weight(g)	37.69±1.17 <sup>b</sup>	34.74±0.69 <sup>b</sup>	42.03±6.54 <sup>ab</sup>	47.60±2.68 <sup>a</sup>	<b>48.99±2.59<sup>a</sup></b>
Weight gain(g)	11.96±0.89 <sup>b</sup>	9.10±1.02 <sup>b</sup>	16.47±5.0 <sup>ab</sup>	22.36±1.28 <sup>a</sup>	<b>23.97±1.31<sup>a</sup></b>
Specific growth rate(%/day)	0.69±0.09 <sup>b</sup>	0.76±0.07 <sup>b</sup>	0.85±0.21 <sup>ab</sup>	1.01±0.04 <sup>ab</sup>	<b>1.13±0.02<sup>a</sup></b>
Food conversion Ratio	0.86±0.16 <sup>b</sup>	1.58±0.18 <sup>ab</sup>	1.73±0.55 <sup>ab</sup>	2.03±0.18 <sup>ab</sup>	<b>2.36±0.07<sup>a</sup></b>
Protein efficiency Ratio	0.27±0.02 <sup>b</sup>	0.27±0.02 <sup>b</sup>	0.37±0.12 <sup>ab</sup>	0.50±0.03 <sup>a</sup>	<b>0.54±0.03<sup>a</sup></b>
Survival Rate (%)	86.67±6.67 <sup>ab</sup>	96.67±3.33 <sup>a</sup>	90.00±10.00 <sup>a</sup>	90.00±5.77 <sup>a</sup>	<b>100.00±0.00<sup>a</sup></b>

Means within rows with different superscript are significantly different (p<0.05).

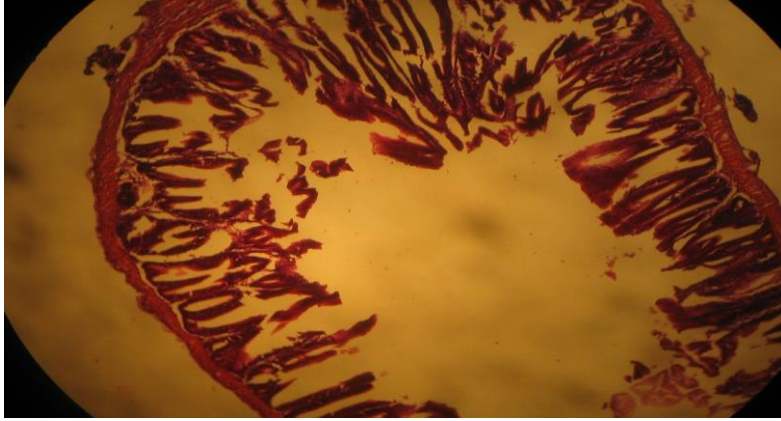
**Table 5.** Haematological profile of *O. niloticus* juvenile fed melon shell Peel (MSP) meal based diets

Parameter	TD1 (0%MSP)	TD2 (25%MSP)	TD3 (50%MSP)	TD4 (75%MSP)	TD5 (100%MSP)
PCV (%)	31.00±0.58 <sup>a</sup>	27.33±0.67 <sup>b</sup>	16.67±1.20 <sup>d</sup>	24.33±0.33 <sup>c</sup>	32.00±1.15 <sup>a</sup>
Hb (g.dL <sup>-1</sup> )	10.10±0.17 <sup>a</sup>	9.17±0.12 <sup>b</sup>	5.37±0.20 <sup>d</sup>	8.03±0.03 <sup>c</sup>	10.33±1.17 <sup>a</sup>
WBCx10 <sup>9</sup> L	5.40±0.15 <sup>b</sup>	3.37±0.12 <sup>d</sup>	8.10±0.12 <sup>a</sup>	2.57±0.15 <sup>e</sup>	4.23±0.12 <sup>c</sup>
RBCx10 <sup>12</sup> L	6.03±0.15 <sup>b</sup>	6.00±0.15 <sup>b</sup>	5.33±0.18 <sup>c</sup>	7.17±0.07 <sup>a</sup>	5.53±0.27 <sup>bc</sup>
PLTx10 <sup>4</sup> mm <sup>3</sup>	2.43±0.03 <sup>c</sup>	3.50±0.06 <sup>a</sup>	1.73±0.03 <sup>e</sup>	2.70±0.06 <sup>b</sup>	2.27±0.03 <sup>d</sup>

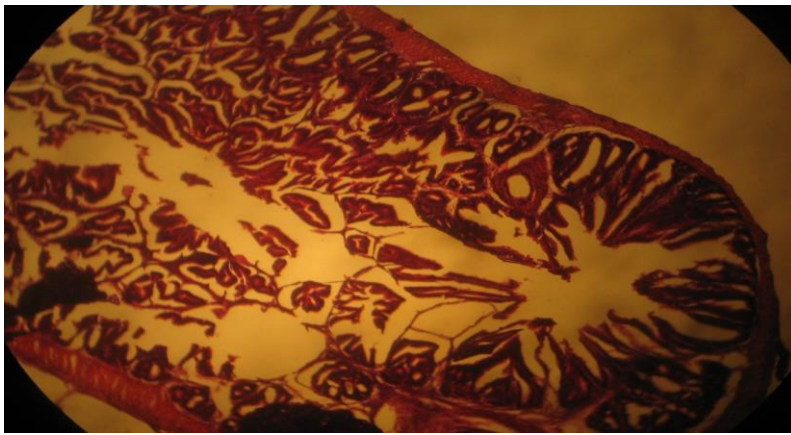
Means within rows with different superscript are significantly different (P<0.05). PCV = Pack Cell Volume, Hb= Haemoglobin, RBC =Red Blood Count, WBC= White Blood Cell and PLT =Platelet.

**Figure 1.** Photomicrograph (H & E 100x) of the intestine of *O. niloticus* fed with the control diet.**Figure 2.** Photomicrograph (H & E 100x) of the intestine of *O. niloticus* fed with 25% MSP dietary inclusion level.

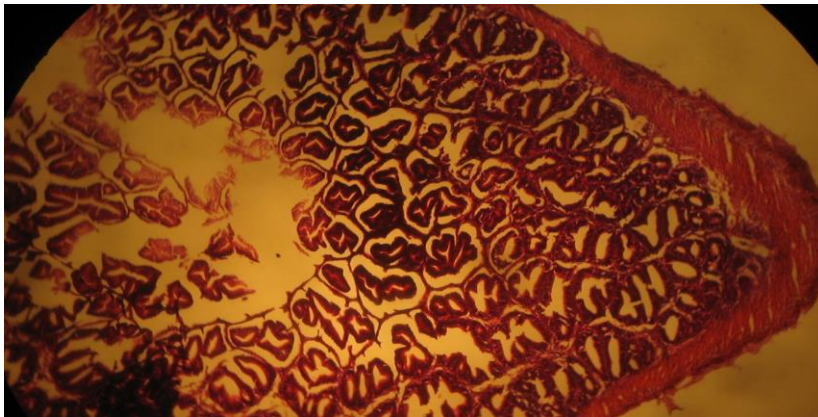




**Figure 3.** Photomicrograph (H & E 100x) of the intestine of *O. niloticus* fed with 50% MSP dietary inclusion level.



**Figure 4.** Photomicrograph (H & E 100x) of the intestine of *O. niloticus* fed with 75% MSP dietary inclusion level.



**Figure 5.** Photomicrograph (H & E 100x) of the intestine of *O. niloticus* fed with 100% MSP dietary inclusion level.

changes especially at the tip of the villi were noticed in diet 2 (25% MSP) and 3 (50% MSP) (plate 2 and 3). This was also followed by the loss of structural integrity of the cell and sloughing of mucosal layer. The reason for the changes cannot be explained. There was no sign of degeneration of mucosal layer and villi in the intestines of the fish fed 75% and 100% MSP (plate 4 and 5). The structural integrity of the cell is intact and villi remain separated. Although

mild changes such as slight erosion of the villi were noticed, it is not likely to impair digestion process since the mucosal layer responsible for secretion of digestive enzymes was not destroyed (plate 5). This further implies that the peptide hormone (cholecystokinin) was not adversely altered as well. Cholecystokinin (CCK) is produced by specific endocrine cells found in the intestinal mucosa (Kamisaka *et al.*, 2003), and plays important role in

the digestive structure of fish and other vertebrates (Murkshita, Kurokawa, Nilsen, & Ronnestead, 2009; Webb, Khan, Nunez, Ronnestad, & Holt, 2010; Micale et al., 2014).

## Conclusion

Research for alternative energy source in fish diet has become imperative as the conventional feedstuffs are expensive and farmers can no longer afford their use in fish diets. The present study has clearly shown that melon seed peel increased growth and haematological indices. Histological examination of the fish revealed that melon seed peel even at 75 and 100% dietary inclusion levels had no deleterious effect on the fish, thus did not adversely altered the normal digestive process and the peptide hormone (cholecystotkinin) in the intestinal mucosa. This is to affirm that melon seed peel can replace maize as energy source in the diet of *Oreochromis niloticus*.

## Acknowledgement

The authors are grateful to Miss Umah Oluchi for type-setting the manuscript.

## References

- AOAC (2000). Official Methods of Analysis of Balarin, J.D. and Haller R. D (1982): The Intensive culture of tilapia in tanks, receiving cases in recent advances in aquaculture. (Eds. J.F. Mur, R.K Roberts), London Croon Helm Ltd, 260-360.
- Abaelu, A.M, Makinde, M.A., & Akinrimisi, E.O. (1979). Melon (egusi) seed protein 1: Study of amino acid composition of defatted meal. *Nutrition Rep. International*. 20: 605-613.
- Abowei, J.F.N, & Ekubo, A.T. (2011). A Review of Conventional and Unconventional Feeds in Fish Nutrition, *British Journal of Pharmacology and Toxicology*, 2 (4): 179-191.
- Agbebi, A.I., Llesanmi, W.O., Adegbeleye, D.O., Odulate, S.O, Obasa, A.I., & Olaoye, O.J.(2003). Growth and haematological effects of replacing Maize with feed wastes on the juvenile *C. gariepinus* (Burchell, 1822), *Journal of Fisheries and Aquatic Science*, 8 : 535-543.  
<https://www.scialert.net/abstract/?doi=jfas.2013.535.543>
- Bahmani, M., Kazemi, R., & Donskaya, P., (2001). A comparative study of some haematological features in young reared sturgeons (*Acipenser persicus* and *Huso huso*). *Fish Physiology and Biochemistry*, 24: 135-140. doi:10.1023/A:1011911019155
- Belelander ,G., & Ramaley, J.A. (1979). Essentials of Histology. C.V. Moebly Company, St. Louis Toronto, London
- Chomiccki, G., & Renner, S.S. (2014). Watermelon origin solved with molecular phylogenetics including Linnaean material: Another example of museomics, *New Phytologist*. 205 (2): 526-32. doi:10.1111/nph.13163
- Dacie, J.V., & Lewis, S.M. (2011). Practical hematology. 11<sup>th</sup> edition, New York: Churchill Livingstone, pp 41.
- El-Sayed, A.F.M., 2006. Tilapia culture. CAB International, Wallingford.
- Erhunmwunse, N.O., & Ainerua, M.O. (2013). Characterization of some blood parameters of African Catfish (*Clarias gariepinus*), *American-Eurasian Journal of Toxicological Sciences*, 5(3):72-76. DOI: 10.5829/idosi.ajejts.2013.5.3.82159
- Ezenwa, B.I.O., & Kusemiju, K., (1985). Seasonal changes in the gonads of the catfish, *Chrysichthys nigrodigitatus* (Lacepede) in Badagry Lagoon Nigeria. *Biologia Africana*, 2: 15 – 23.
- Fagbenro, O.A. (1987). A review of biological and economical principles underlying commercial fish culture production in Nigeria. *Journal of West African Fisheries* 3: 171-177.
- Fagbenro, O.A. (2004). Predator control of overpopulation in cultured tilapias and the alternative uses for stunted tilapias in Nigeria. Proceedings of the Sixth International Symposium on Tilapia in Aquaculture, pp.634-647. (R.B. Bolivar, G.C. Mair and K. Fitzsimmons, eds.). Manila, Philippines. September 12-16, 2004.
- Falaye, A.E. (1992). Utilization of Agro-industrial wastes as fish feedstuffs in Nigeria. Proceeding of the 10th Annual Conference of FISON pp 47 – 57.
- Food and Agriculture Organisation, (2010). Fisheries and Aquaculture Department Food and Agriculture Organization of the United Nations. The State of World Fisheries and Aquaculture.
- Gabriel, U.U., Akinrotimi, O.A., Bekibele, D.O, Onunkwo, D.N, & Anyanwu, P.E., (2007). Locally produced fish feed, potentials for aquaculture development in sub-Saharan. *African Journal of Agricultural Research* 297; 287-295. Doi: 10.5897/AJAR.
- Haque, S., Pal, S., Mukherjee, A.K., & Ghosh, A.R. (2012). Histopathological and ultramicroscopic changes induced by Fluoride in soft tissue organs of the air-breathing teleost, *Channa punctatus* (Bloch), *Research Report Fluoride* 45(3) 263-273.
- Houlihan, D., Bouiard, T., & Jobling, M. (2001). Food Intake in Fish. 2001 eds. Iowa State University Press. Blackwell Science Ltd. 418 pp.
- Iheanacho, S.C., Ogunji, J.O., Ogueji, E.O., Nwuba, L.A., Nnatuanya, I.O., Ochang, S.N., Mbah, C.E., Usman, I.B., & Haruna, M. (2017). Comparative assessment of ampicillin antibiotic and ginger (*Zingiber officinale*) effects on growth, haematology and biochemical enzymes of *Clarias gariepinus* Juvenile. *Journal of Pharmacognosy and Phytochemistry*. 6(3): 761-767.
- Ikwor, T.N., & Nwakpa, J.N. (2008). Floating capacity, growth and haematology of *C. Gariepinus* fingerlings fed different levels of melon peel diets. Abstract of *World Aquaculture Society*, 2016.
- Kamisaka, Y., Fuji, Y., Yamamoto, S., Kurokawa, T., Ronnestad, I., Totland, G.K., Tagawa, M., & Tanaka, M. (2003). Distribution of Cholecystokinin-Immunoreactive cells in the digestive track of the Larval teleost, ayu, *Pleciglossue altivelis*. *General Comparative Endocrinology*, 134, 116-121. <http://doi.org/10.1016/j.cbpb.200611.009>
- Micale, V., Campo, S., D'Ascola, A., Guerrero, M.C., Levanti, M.B., Germanà, A., & Muglia, U., (2014). How many functions? Observations in seabreams. *General and Comparative Endocrinology*, 205, 166-167. <http://doi.org/10.1371/journal.pone.0052428>

- Murashita, K., Kurokawa, T., Nilsen, T.O., & Ronnestead, I., (2009). Ghrelin, Cholecystokinin and peptide YY in Atlantic Salmon (*Salmo salar*): Molecular cloning and tissue expression. *General Comparative Endocrinology*, 160, 223-235. <http://doi.org/10.1016/j.cbpb.200611.009>
- Nguyen, T., Davis, D.A., & Saoud, I.P. (2009). Evaluation of alternative protein sources to replace fish meal in practical diets for juvenile tilapia, *Oreochromis spp.* Retrieved from <https://www.was.org.html>
- Nwanna, L.C.I., Falaye, A.E., Olarewaju, O.J., & Oludapo, B.V. (2009). Evaluation of Nile Tilapia (*Oreochromis niloticus* L) fed dietary potato peels as replacement for yellow maize. FISON Conference proceedings :156-159
- Obi, M. N., Kolo, R.J., & Orire, A.M. (2011). The production of floating fish feed using melon shell as a floating agent. *International Journal of Science and Nature*, 2 (3) 477-482. ISSN 2229-6441.
- Ogunlade, I. (2007) Backyard Fish Farmers Information needs in Osun State, Nigeria. AAAE Conference proceedings (2007) 165-169
- Orire, A.M., & Ricketts, O.A. (2013). Utilisation of Melon shell as dietary energy source in the diet of Nile Tilapia (*Oreochromis niloticus*) *International Journal of Engineering and Science* 2 (4) 05-11.
- Sogbesan, A.O., & Ugwumba, A.A.A. (2008). Nutritional evaluation of termite (*Macrotermes subhyalinus*) meal as animal protein supplements in the diets of *Heterobranchus longifilis* (Valenciennes, 1840) fingerlings. *Turkish Journal of Fisheries and Aquatic Sciences*, 8, 149-157. [http://dx.doi.org/10.4194/13032712 v16\\_4\\_31](http://dx.doi.org/10.4194/13032712 v16_4_31)
- Steven C., & Louis, A. H. ( 2002). Understanding Fish Nutrition, Feeds, and Feeding.
- Tsevis, A.A., & Azzaydi, T.A. (2000). Effect of feeding regime on selected species of fish. Article publication of FISON, Feb., 2000. Agora Site.
- Webb, J.K.A., Khan, A., Nunez, B.S., Ronnestad, I., & Holt, G.J. (2010). Cholecystokinin: Molecular cloning and Immunohistochemical localization in the gastrointestinal tract of Larval Red drum, *Sciaenops ocellatus* (L). *General Comparative Endocrinology*, 166, 152-159. Doi: 10.1016/j.ygcen.2009.10.010