



Histological Changes of Korean Rose Bitterling (*Rhodeus uyekii*) Organs in the Early Growth Period

In Bon Goo^{1*}, Ju-ae Hwang¹, Do Hee Kim¹, Jeong Ho Lee¹, Hye-Sung Choi¹, Sang Gu Lim², Hyoung Kyun Han³, Hyun Woo Gil⁴, In-Seok Park⁴

¹Inland Aquaculture Research Center, National Institute of Fisheries Science (NIFS), Changwon 51688, Korea.

²Future Aquaculture Research Center, NIFS, Jeju 63068, Korea.

³Tidal Flat Research Center, NIFS, Gunsan 54014, Korea.

⁴Korea Maritime and Ocean University, Division of Marine Bioscience, Busan 49112, Korea.

* Corresponding Author: Tel.: +82.514 104321; Fax: +82.514 044750;
E-mail: bourne@kmou.ac.kr

Received 01 September 2016
Accepted 05 December 2016

Abstract

Histological changes in the Korean rose bitterling (*Rhodeus uyekii*) organs during the early period of growth were observed in this study. Regarding the retina, this organ was first seen at 5 days post-hatching (DPH) and increased in size up to 53 DPH. The retina consisted of the optic nerve fiber layer (ONFL), ganglion cell layer (GCL), inner plexiform layer (IPL), inner nuclear layer (INL), outer plexiform layer (OPL), outer nuclear layer (ONL), outer limiting membrane (OLM), rod and cone layer (RCL), and epithelial layer (EL). The EL, RCL, OLM, and IPL increased in thickness, whereas the INL remained unchanged and the GCL thinned to 53 DPH. Regarding the kidney, this organ harbors many proximal tubules that appear as hollow ovals or circles upon histological examination of sections. A few small proximal tubules were observed at 5 DPH, and the number and size of proximal tubules increased steadily thereafter. The proximal tubule cells of kidney increased with time, with the minor axes remaining consistently shorter than the major axes throughout this period. With respect to the midgut epithelium, this organ was tightly stretched at 15 DPH, but it became wrinkled and folded by 53 DPH. The tissue density increased with time, and the nuclear height increased continuously from 15 DPH to 53 DPH. With respect to the gill, this organ developed gradually over time, with increases observed in the number and length of gill filaments and the number of gill lamella. These results may provide useful data for the successful breeding and rearing of the Korean rose bitterling.

Keywords: Gill, histology, kidney, retina, *Rhodeus uyekii*.

Introduction

The Korean rose bitterling (*Rhodeus uyekii*) belongs to the family Cyprinidae and is endemic to Korea (Jeon, 1982). It is found in the water systems of the Nakdong River and prefers to live in rivers with slow currents, or on muddy/sandy river bottoms (Jeon, 1982). The males are visually striking, and are popular as aquarium fish. Recently, there has been an urgent demand for conservation of the Korean rose bitterling, which has been adversely affected by exposure to biological and chemical pollutants (Kim & Park, 2002; Kang, Kim, Park, Yang, & Cho, 2006).

In fish larvae, visual function is important for feeding, collective behavior, positioning, and escape from predators (Rodriguez & Gisbert, 2001; Park, Im, Hur, & Jeong, 2006a; Park *et al.*, 2006b). The retinal structure of the teleost does not differ from that of other vertebrates, but the number of teleost species and their differences in habitats, activities, and life cycles has made it difficult for researchers to define a general retinal structure for the Teleostei (Wagner, 1990). The behavioral and environmental factors that

affect different fish are important to their visual ecology, and must be addressed in any study of their visual structures and function (Walls, 1942; Lythgoe, 1979).

For internal organs, such as the kidney or midgut epithelium, development typically proceeds throughout the larval stage in fish (Blaxter, 1988). Numerous studies have examined various parameters of early development in teleost species, such as: early growth and yolk absorption in the rainbow trout (*Oncorhynchus mykiss*) (Park, Im, & Jang, 1996) and chum salmon (*O. keta*) (Zhang, Sohn, Seong, & Park, 1995); the early development of eye in the dotted gizzard shad (*Konosirus punctatus*) (Park *et al.*, 2006a) and dark-banded rockfish (*Sebastes inermis*) (Park, Park, Gil, & Goo, 2012); and the morphometric and histological changes of the cyprinid loach (*Misgurnus anguillicaudatus*) (Han *et al.*, 2013). However, few studies have touched on the early organ development of the Korean rose bitterling.

Various aspects of the Korean rose bitterling have been reported, including: the early life history of laboratory-reared fish; the temperature-dependent

index of mitotic interval (τ_0) for chromosome manipulation; egg and larval development; the seasonal sex ratio; the reproductive cycle; osteology; ovipositor elongation; and morphometric traits and cytogenetic analysis in induced crosses and reciprocal hybrids of *R. uyekii* and *R. notatus* (Kim & Han, 1990; Park & Kim, 1990; An, 1995; Kim, 1997; Chae, 2001; Kim, Lim, Gil, & Park, 2011; Kim, Kang, Jang, & Park, 2012).

Among the organs of a teleost, the gill, which is comprised of the gill arches, gill filaments and lamella, acts as the essential respiratory organ for life under water and thus develops early in the growth process. Other important organs relate to food absorption. It is well recognized that the successful rearing of larval fish requires that the feeding strategies, culture conditions, and survival rates be considered in terms of the ontogenetic status. The early survival rates of fish are affected by the success or failure of their first feeding, when the larvae transition from endogenous (yolk sac) feeding to exogenous feeding (O'Connell, 1976; Theilacker, 1978; Strüssmann & Takshima, 1990). Thus, to increase the early survival rate, we need to understand alimentary tract development and organogenesis, and how it relates to the exact timing of yolk sac absorption and the transition to exogenous feeding. The Korean rose bitterling exhibits high levels of hatchery mortality during the early life stages of reared larvae, but we currently lack any detailed report on the anatomy of this species beyond those describing histological changes that occur in the developing larvae.

Given this lack, the present report seeks to describe the histological changes that occur in the gill, kidney, midgut epithelium, and retina of the developing Korean rose bitterling.

Materials and Methods

Korean rose bitterling (*Rhodeus uyekii*) brood stocks were reared at the Inland Aquaculture Research Center, National Institute of Fisheries Science, Changwon, Korea. The fish were reared in a glass tank (W 120 cm x L 30 cm x H 50 cm) until the experiment was initiated. The water temperature was maintained at $20 \pm 1^\circ\text{C}$. During the spawning season of 2013 (late April to mid-June), densely colored males and ovipositor-extended female were selected and used as brood stock. Eggs were obtained by abdominal compression of ovipositor-extended females, semen was obtained by abdominal compression of males and insemination within 2 minutes.

Plastic tanks (Fresh Plus, Mirae Chemical, Korea; W 30 cm x L 20 cm x H 15 cm) were loaded with 200 eggs each and maintained at a water depth of 10 cm and a L:D ratio of 13:11. The water was replaced twice daily with aerated bottled water

(Natural Mineral Water, Pulmuone, Korea), and the water temperature was maintained at $22 \pm 0.5^\circ\text{C}$. Each day, integral water temperature was recorded. Upon hatching, groups of 10 larvae were transferred to transparent plastic containers (Coolrara, Easyfilm, Korea; W 10 cm x L 5 cm x H 3 cm) and reared under the above-described water and monitoring conditions. Upon complete absorption of the yolk at 21 days post-hatching (DPH), the larvae were fed with *Artemia* sp.

Newly hatched larvae ($n=20$) were sampled daily from hatching to 5 DPH, at 2-day intervals from 7 to 21 DPH, at 4-day intervals from 25 to 41 DPH, at 6-day intervals from 47 to 83 DPH, and at 30-day intervals from 110 to 170 DPH. At various points, larvae were collected and anesthetized with 300 ppm lidocaine-HCl/NaHCO₃ at 25°C according to the method of Park, Kim, Kim and Kim (1988). Body weight (BW) and total length (TL) were measured to the nearest 0.01 g (AX 200, Shimadzu Corp., Japan) and 0.1 mm (CD-20 CP; Mitutoyo, Japan), respectively.

For histology, each sample of whole fish was fixed in Bouin's solution for 24 h, washed with water, processed in decalcification solution (Solution A: Solution B=1:1, Solution A=Sodium citrate 200 mg+Distilled water 1,000 mL; Solution B=88% formic acid 500 mL+Distilled water 500 mL) for 24 h, washed with flowing water again, and dehydrated through a graded series of alcohol (70%, 80%, 90%, and 100% ethanol for 1 h each). The samples were then cleared with xylene, impregnated with soft paraffin, impregnated with hard paraffin, embedded, trimmed, cut, and stained with hematoxylin-eosin. Finally, the samples were mounted with Canadian balsam and examined under optical microscopy (AxioCam MR, Carl Zeiss, Germany).

At time points ranging from just hatched to 170 DPH, samples were randomly collected. The retinal thickness was measured using an eyepiece micrometer under optical microscopy (x1,000; Carl Zeiss, Germany) and the proportional thicknesses of retinas was calculated using the method of Park *et al.* (2006b). To monitor the development of the midgut epithelium, kidney, and gill, an optical microscope camera (AxioCam MR, Carl Zeiss, Germany) was used to measure the areas and volumes of cells and nuclei using the formulae, $\text{surface area} = 1/4 \times ab\pi$ and $\text{volume} = 4/3 \times \pi(a/2) \times (b/2)^2$, where a and b are the major and minor axes of the cell or nucleus (Park & Kim, 2000). Photographs of the eye, kidney and midgut epithelium in specimens of each stage were processed using the Axioskop 4.1 image analysis software (Carl Zeiss, Germany). Gill development was observed by counting the gill filaments, counting the number of secondary lamella per gill filament, measuring the lengths of the gill filaments, and assessing their relationships.

Each experiment was practiced in triplicate and the results are reported as means \pm SD ($n=20$), unless

otherwise stated. The data were analyzed with one-way ANOVA using the SPSS statistical package (SPSS 9.0, SPSS Inc., Chicago, IL, USA). Means were compared with Duncan's multiple range test, and were considered significantly different at $P < 0.05$.

Results

In the Korean rose bitterling (*Rhodeus uyekii*), yolk absorption was complete at 21 DPH (462°C Integral Water Temperature, IWT), and the hatchlings exhibited the larval form at this point. Table 1 lists the component layers of the retina observed from 5 DPH (110°C IWT) to 170 DPH (3,740°C IWT). The thickness of the retina continuously increased from 17.4 μm at 5 DPH to 22.9 μm at 170 DPH (3,740°C IWT) ($P < 0.05$). The retina consisted of the optic nerve fiber layer (ONFL), ganglion cell layer (GCL), inner plexiform layer (IPL), inner nuclear layer (INL), outer plexiform layer (OPL), outer nuclear layer (ONL), outer limiting membrane (OLM), rod and cone layer (RCL), and epithelial layer (EL). The thicknesses of the EL, RCL, OLM, and IPL gradually increased with development, whereas that of the INL remained constant and the GCL decreased in thickness between 5 DPH and 170 DPH ($P < 0.05$).

Table 2 lists the nuclear heights of the midgut epithelium cells and the dimensions of the proximal renal tubules of the kidney at 15 DPH (330°C IWT), 29 DPH (638°C IWT), 41 DPH (902°C IWT), 53 DPH (1,166°C IWT), 83 DPH (1,826°C IWT), 110 DPH (2,420°C IWT) and 170 DPH (3,740°C IWT). The nuclear height in the midgut epithelium increased continuously from 15 DPH to 53 DPH ($P < 0.05$). The each axes of the proximal tubule cells in the kidney increased with time, with the major axes remaining longer than the minor axes throughout this period ($P < 0.05$). The surface areas and volumes of the

proximal tubule cells in the kidney, which were calculated from the major and minor axes also increased with time ($P < 0.05$).

Figure 1 shows the histological changes in the retina of the Korean rose bitterling between 5 DPH and 170 DPH. At 5 DPH, the retina exhibited a much looser layer structure than that observed at 170 DPH, with the densities of the RCL, OLM and ONL showing particular increases during this period.

Figure 2 shows the histological changes observed in the kidney and midgut epithelium at 15 DPH and 170 DPH. The proximal tubules were relatively few and small at 5 DPH (Figure 2A), and increased in number and size thereafter (Figure 2B). Figure 2B shows a 170-DPH kidney, which has more and larger proximal tubules than the 15 DPH kidney shown in Figure 2A. Midgut epithelium was tightly stretched at 15 DPH (Figure 2C), but became denser, wrinkled, and folded by 53 DPH (Figure 3D). The relationship between TL and IWT, which is shown in Figure 3, could be described by the linear function, $Y = 0.007X + 5.463$ ($R^2 = 0.965$), where Y is TL and X is IWT. Yolk absorption was complete at 9.2 mm TL (462°C IWT).

As shown Figure 4, the gill anlage of the developing Korean rose bitterling could be discerned in the region of the closed buccopharyngeal cavity (Figure 4A). At 1 DPH, the four primordial gill arches were distinguishable (Figure 4B). At 3 DPH, the observable gill structures comprised cores of chondroblasts covered with undifferentiated epithelium, and the pharynx had opened (Figure 4C). At 7 DPH, four separate gill arches could be clearly distinguished. These structures proliferated towards a cavity formed by the primary lamellae with captured blood vessels (Figure 4D). At 9 DPH, the pseudobranch anlage was first observed as a structure of undifferentiated cells. It continued to develop, and

Table 1. Thickness of each component layer of the retina in the Korean rose bitterling, *Rhodeus uyekii*, from hatching to 170 days post-hatching (DPH)*

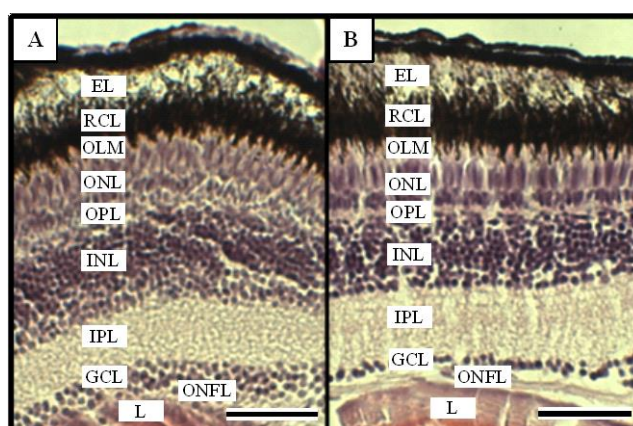
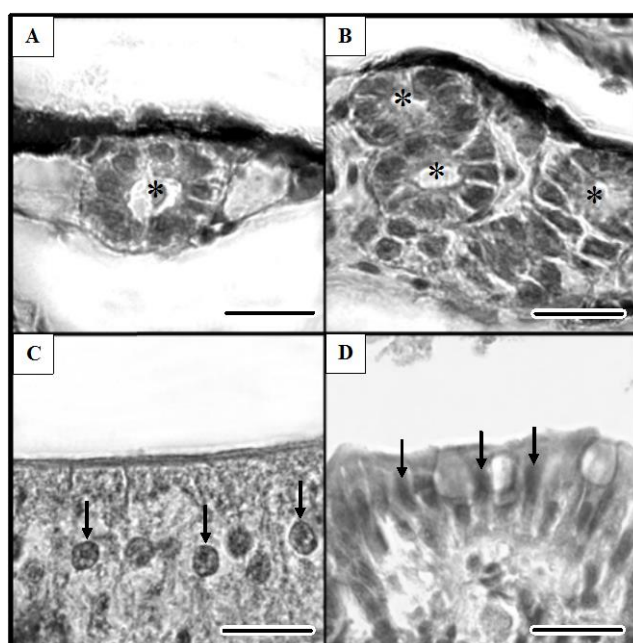
	DPH						
	5	15	29	53	83	110	170
Thickness of retina (μm)	17.4 \pm 1.24 ^a	19.2 \pm 1.88 ^a	21.4 \pm 2.42 ^{ab}	22.7 \pm 2.11 ^b	22.8 \pm 1.21 ^b	23.1 \pm 1.31 ^b	22.9 \pm 1.01 ^b
	Thickness of each component layer (%)						
Epithelial layer	9.0 \pm 0.13 ^b	8.1 \pm 0.19 ^a	9.6 \pm 0.31 ^b	10.7 \pm 0.28 ^c	9.5 \pm 0.28 ^b	10.5 \pm 0.28 ^c	11.7 \pm 0.28 ^c
Rod and cone layer	8.8 \pm 0.28 ^b	8.1 \pm 0.43 ^a	9.8 \pm 0.87 ^c	9.3 \pm 1.10 ^{bc}	10.5 \pm 1.10 ^c	11.5 \pm 1.10 ^c	11.0 \pm 1.10 ^c
Outer limiting membrane layer	8.7 \pm 0.13 ^a	8.5 \pm 0.18 ^a	8.9 \pm 0.24 ^{ab}	8.7 \pm 0.35 ^a	10.8 \pm 0.35 ^b	10.8 \pm 0.35 ^b	10.7 \pm 0.35 ^b
Outer nuclear layer	6.1 \pm 0.53 ^c	5.2 \pm 0.43 ^b	5.1 \pm 0.35 ^b	5.2 \pm 0.21 ^b	4.8 \pm 0.21 ^b	4.1 \pm 0.21 ^b	3.2 \pm 0.21 ^a
Outer plexiform layer	16.7 \pm 0.67 ^b	16.1 \pm 0.53 ^b	15.3 \pm 0.41 ^b	14.7 \pm 0.35 ^b	11.2 \pm 0.29 ^{ab}	8.7 \pm 0.21 ^a	4.5 \pm 0.21 ^a
Inner nuclear layer	22.7 \pm 0.53 ^a	22.6 \pm 0.48 ^a	22.8 \pm 0.40 ^a	22.0 \pm 0.38 ^a	22.4 \pm 0.38 ^a	22.4 \pm 0.38 ^a	24.3 \pm 0.38 ^a
Inner plexiform layer	14.1 \pm 0.69 ^a	22.0 \pm 0.81 ^b	23.1 \pm 0.98 ^b	24.7 \pm 1.30 ^c	25.2 \pm 1.30 ^c	25.2 \pm 1.30 ^c	25.7 \pm 1.30 ^c
Ganglion cell layer	8.7 \pm 0.53 ^a	8.1 \pm 0.58 ^b	5.9 \pm 0.41 ^c	2.7 \pm 0.34 ^d	3.6 \pm 0.34 ^d	3.6 \pm 0.34 ^d	2.2 \pm 0.34 ^d
Optic nerve fiber layer	2.3 \pm 0.13 ^a	2.5 \pm 0.19 ^a	3.3 \pm 0.23 ^b	4.0 \pm 0.37 ^c	3.9 \pm 0.31 ^c	3.9 \pm 0.29 ^c	3.8 \pm 0.35 ^c

*The values are presented as the means \pm SD ($n = 50$) of triplicate groups. Differences among the experimental groups were significant at this level. Within each column, the values that do not share a superscript letter are significantly different ($P < 0.05$).

Table 2. Changes of cell size in the proximal tubules of kidneys and of nuclear height in the midgut epithelium of the Korean rose bitterling, *Rhodeus uyekii* from hatching to 170 DPH*

	DPH						
	15	29	41	53	83	110	170
Nuclear height of midgut epithelium (μm)	1.6 \pm 0.34 ^a	1.9 \pm 1.81 ^a	3.1 \pm 2.05 ^b	4.9 \pm 2.13 ^c	5.0 \pm 1.13 ^c	5.1 \pm 0.93 ^c	5.0 \pm 1.33 ^c
Proximal tubule cell of kidney							
Major axis (μm)	2.1 \pm 0.22 ^a	2.6 \pm 0.39 ^b	2.8 \pm 0.64 ^c	3.1 \pm 0.31 ^d	3.2 \pm 0.99 ^d	3.1 \pm 0.86 ^d	3.1 \pm 0.79 ^d
Minor axis (μm)	1.8 \pm 0.36 ^a	2.1 \pm 0.30 ^a	2.2 \pm 0.39 ^b	2.3 \pm 0.51 ^b	2.2 \pm 0.47 ^b	2.2 \pm 0.61 ^b	2.2 \pm 0.48 ^b
Surface area (μm^2)	2.9 \pm 0.41 ^a	4.3 \pm 0.69 ^b	4.8 \pm 0.61 ^c	5.5 \pm 0.57 ^d	5.6 \pm 0.58 ^d	5.5 \pm 0.52 ^d	5.5 \pm 0.49 ^d
Volume (μm^3)	3.7 \pm 0.44 ^a	6.0 \pm 0.75 ^b	7.0 \pm 0.81 ^c	8.6 \pm 0.94 ^d	8.5 \pm 0.84 ^d	8.5 \pm 0.82 ^d	8.6 \pm 0.88 ^d

*The values are presented as the means \pm SD ($n=30$) of triplicate groups. Differences among experimental groups are significant at this level. Within each column, the values that do not share a superscript letter are significantly different ($P<0.05$). Surface area= $1/4 \times ab\pi$ and volume= $4/3 \times \pi(a/2) \times (b/2)^2$, where a and b are the major and minor axes, respectively, of the cell or nucleus (after Park and Kim, 2000).

**Figure 1.** Histological sections of the eye of the Korean rose bitterling, *Rhodeus uyekii*. A: Retina at 5 days post-hatching (DPH). B: Retina at 170 DPH. Abbreviations: EL, epithelial layer; GCL, ganglion cell layer; INL, inner nuclear layer; IPL, inner plexiform layer; L, lens; OLM, outer limiting membrane; and RCL, rod and cone layer. Scale bars=5 μm .**Figure 2.** Histological sections of the kidney and midgut epithelium of the Korean rose bitterling, *Rhodeus uyekii*. A: Kidney at 15 DPH. B: Kidney at 53 DPH. C: Midgut epithelium at 15 DPH. D: Midgut epithelium at 53 DPH. Symbols: *, proximal tubule cells of kidney; arrows, midgut epithelial cell nuclei. Scale bars=5 μm .

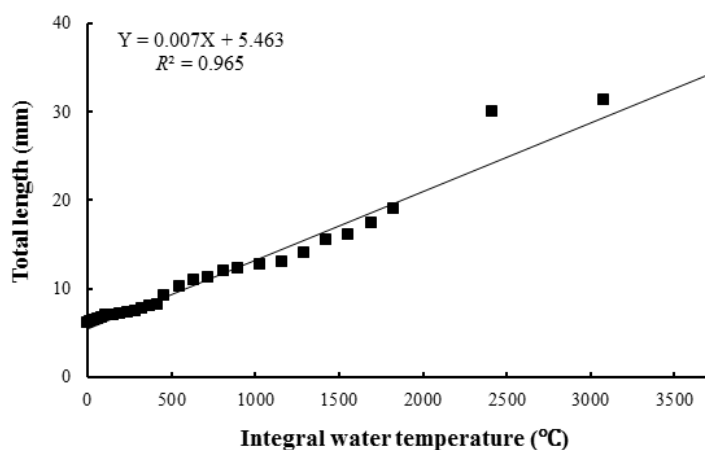


Figure 3. Relationship between the total length of the Korean rose bitterling, *Rhodeus uyekii* and the integral water temperature from hatching to 170 DPH.

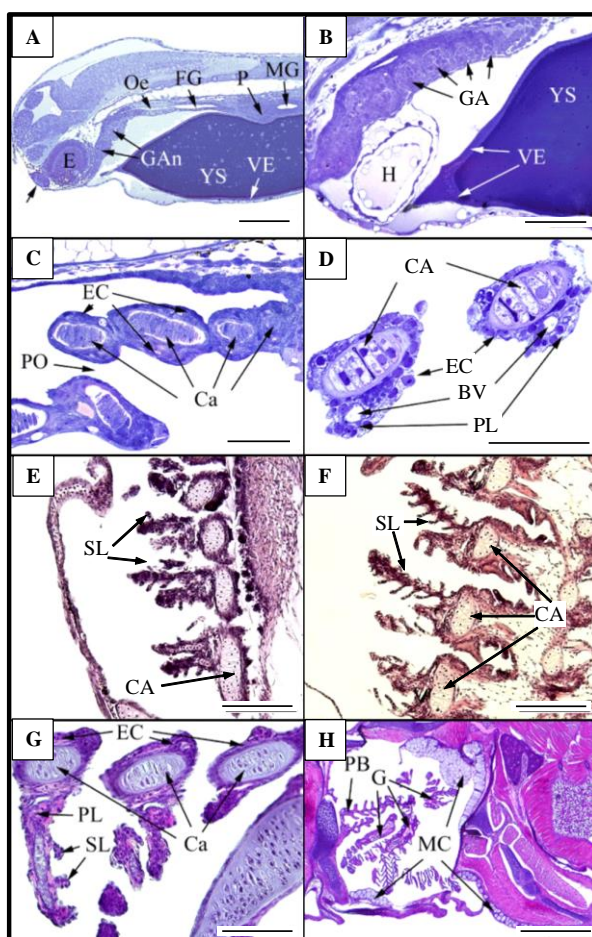


Figure 4. Histological sections of Korean rose bitterling, *Rhodeus uyekii* larvae during the growth period. A: Larva at hatching. B: Gill arches at 1 DPH. C: Gill arches at 3 DPH. D: Gill arches at 7 DPH. E: Gill arches at 16 DPH. F: Gill arches at 22 DPH. G: Gill arches at 29 DPH. H: Gill arches at 49 DPH. Abbreviations: BV, blood vessel; Ca, cartilage; E, eye; EC, epithelial cell; FG, foregut; G, gill; GA, gill arch; GAn, gill arch anlage; H, heart; MC, mucous cell; MG, midgut; OE, olfactory; Oe, esophagus; P, pancreas; PB, pseudobranch; PL, primary lamella; PO, pharynx opening; SL, secondary lamella; VE, vitelline envelope; and YS, yolk sac. Scale bars = 50 μ m.

by 25 DPH, proliferating filaments and lamellae were evident. Cross-sections of gill arches revealed the presence of developing gill filaments at 16 DPH

(Figure 4E) and developing secondary lamellae at 22 DPH (Figure 4F). By 29 DPH, anlagen of secondary lamellae were observed in the gill filaments (Figure

4G). By 49 DPH, the gill had noticeably increased in length, as well as in the numbers of filaments and lamellae (Figure 4H).

The mean number of gill filaments and TL exhibited the linear relationship, $Y=0.718X+9.301$ ($R^2=0.572$), where Y is the number of gill filaments and X is TL (Figure 5). The number of gill filaments increased rapidly once the TL exceeded 9.2 mm. Figure 6 shows the relationship between the gill

filament length and TL; this linear function corresponded to $Y=17.75X+73.78$ ($R^2=0.956$), where Y is the gill filament length and X is TL. Finally, the relationship between the number of secondary lamellae per gill filament and TL could be described by the equation, $Y=0.000X^4-0.041X^3+1.154X^2-11.17X+41.93$ ($R^2=0.987$), where Y is the number of secondary lamellae per gill filament and X is TL (Figure 7).

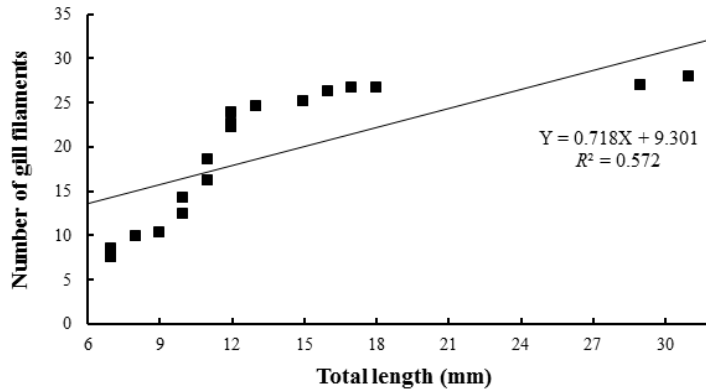


Figure 5. Relationship between the mean number of gill filaments and total length of the Korean rose bitterling, *Rhodeus uyekii* from just hatching to 170 DPH.

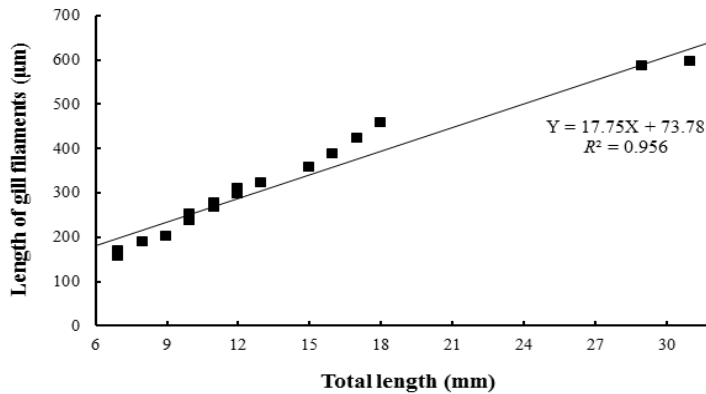


Figure 6. Relationship between gill filament length and total length in the Korean rose bitterling, *Rhodeus uyekii* from just hatching to 170 DPH.

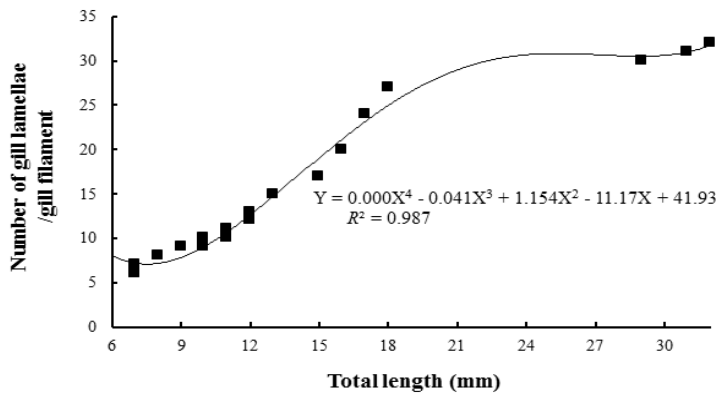


Figure 7. Relationship between the number of secondary lamellae per gill filament and the total length of the Korean rose bitterling, *Rhodeus uyekii* from just hatching to 170 DPH.

Discussion

In the teleost, the eye usually grows into adulthood, but the optical characteristics of its components stabilize in the early days of development (Han *et al.*, 2013). The present study found that the eyes of the Korean rose bitterling (*Rhodeus uyekii*) were completely formed at 5 DPH. Their retinas are composed of nine layers (ONFL, GCL, IPL, INL, OPL, ONL, OLM, RCL, and EL) (Figure 1), each of which resembled those of other cyprinid fish (Takashi, 1982). In this study, tendency of most aspects of the eye tissues were similar in the two species, mud loach (*Misgurnus mizolepis*) and cyprinid loach (*M. anguillicaudatus*), particularly the OLM, although there were significant differences in the RCL and INL, which is coincidental with the observations of Park and Kim (2000). Similar research has been conducted in the dark-banded rockfish (*Sebastes inermis*), in which the RCL did not change significantly during development, but the OLM showed a significant increase (Park *et al.*, 2012). Similar results were obtained in the cyprinid loach (Han *et al.*, 2013). However, thickness of layer shows difference in this study comparison to other species. Based on these results of this study and other researches with the fundamental functions of the retinal components, that were inferred the rates of change in the fish retinal components are related to their physiology and ecology in the early days of their development (Goo, Gil, & Park, 2013). For example, it fish that lives in dark environment like bottom of the river has thin RCL, or lives in light environment fish has thick RCL more than dark environment fish because RCL has substantial photoreceptors, rhodopsin and iodopsin. The fish like the dark environment, mud loach, cyprinid loach, showed a thin RCL at the development of the early retina and tendency to become thicker gradually (Han *et al.*, 2013; Goo *et al.*, 2013).

The early development of internal organs is similar in most teleosts (Blaxter, 1988), although the kidney may form either before or after hatching. The present study showed that the kidneys of the Korean rose bitterling formed at 15 DPH and developed continuously thereafter until 53 DPH. This tendency has because yolk absorption involved in *Rhodeus*, they has usually long yolk absorption period (Jeon, 1982). In the juvenile true ferra (*Coregonus fera*), the yolk sac is completely absorbed by 11 DPH, and throughout this period the absorptive activity of the midgut epithelium begins to function (Loewe & Eckmann, 1988). In the juvenile summer flounder (*Paralichthys dentatus*), the yolk sac is completely absorbed by 3 DPH and the absorptive activity of the midgut epithelium begins to function at 4 DPH (Bisbal & Bengtson, 1995). In the juvenile pike eel (*Muraenesox cinereus*), however, the absorptive function of the midgut epithelium begins at 3 DPH, which is prior to the complete absorption of the yolk

sac. At 3 DPH in this eel, the mucosal fold of the midgut has formed, the microvillus structures of the midgut may be observed under optical microscopy, and active absorption is detectable in these cells, indicating that liquefied nutrients can be absorbed at this time (Otake, Hirokawa, Fujimoto, & Imaizumi, 1995). The present study shows that the midgut of the Korean rose bitterling was first observed at 15 DPH and thereafter gradually grew until 53 DPH. As the yolk sac is completely absorbed at 21 DPH in this species, these results suggest that, similar to the pike eel and cyprinid loach, the absorptive function of the midgut begins before the yolk sac is completely absorbed.

In sum, there has been little research into the early growth of the Korean rose bitterling. The present study examined the histological development of this species up to 170 DPH. Our results may provide useful data for the successful breeding and rearing of the Korean rose bitterling.

Acknowledgments

This work was supported by a grant from the National Institute of Fisheries Science (R2016039).

References

- An, C.M. (1995). Reproductive cycle of the spring-spawning bitterling, *Rhodeus uyekii* (Pisces: Cyprinidae). *Korean Journal of Ichthyology*, 7(1), 33-42.
- Bisbal, G.A., & Bengtson, D.A. (1995). Development of the digestive tract in larval summer flounder. *Journal of Fish Biology*, 47(2), 277-291. <http://dx.doi.org/10.1111/j.1095-8649.1995.tb01895.x>
- Blaxter, J.H.S. (1988). Patterns and variety in development. In W.S. Hoar & D.J. Randall (Eds), *Fish Physiology* (pp. 1-58). New York, USA, Academic Press., 545 pp.
- Chae, B.S. (2001). Elongation of the ovipositor in Korean rose bitterling, *Rhodeus uyekii* (Pisces: Cyprinidae). *Korean Journal of Ichthyology*, 13(2), 111-116.
- Goo, I.B., Gil, H.W., & Park, I.-S. (2013). Comparative Analysis of Histological Changes in Ussurian Bullhead, *Leiocassis ussuriensis*, and Korean Bullhead, *Pseudobagrus fulvidraco*, in the Early Period of Growth. *Development and Reproduction*, 17(4), 427-434. <http://dx.doi.org/10.12717/DR.2013.17.4.427>
- Han, H.K., Lim, S.G., Kang, J.H., Choi, J.W., Gil, H.W., Cho, S.H., Lim, S.Y., & Park, I.-S. (2013). Morphometric and histological changes in cyprinid loach, *Misgurnus anguillicaudatus*, in the early growth period. *Development and Reproduction*, 17(3), 187-198. <http://dx.doi.org/10.12717/dr.2013.17.3.187>
- Jeon, S.R. (1982). Studies on the distribution of the Acheilognathid fishes (Cyprinidae) from Korea. *Annual Report of Biological Research*, 3, 33-47.
- Kang, E.J., Kim, C.H., Park, I.-S., Yang, H., & Cho, Y.C. (2006). Early developmental characteristics of induced hybrids between *Rhodeus uyekii* and *R. notatus* (Pisces: Cyprinidae). *Korean Journal of*

- Ichthyology*, 18(4), 339-346.
- Kim, B.S., Kang, E.J., Jang, H., & Park, I.-S. (2012). Morphometric traits and cytogenetic analysis in induced cross and reciprocal hybrid between *Rhodeus uyekii* and *R. notatus*. *Korean Journal of Ichthyology*, 24(3), 151-159.
- Kim, B.S., Lim, S.-G., Gil, H.W., & Park, I.-S. (2011). Temperature-dependent index of mitotic interval (τ_0) for chromosome manipulation in Korean rose bitterling, *Rhodeus uyekii*. *Journal of Fisheries and Aquatic Sciences*, 14(4), 429-434. <http://dx.doi.org/10.5657/fas.2011.0429>
- Kim, I.J. (1997). A osteological study of *Rhodeus uyekii*. *Korean Journal of Ichthyology*, 9(1), 130-140.
- Kim, I.S., & Park, J.H. (2002). Freshwater Fishes of Korea. Seoul, Korea, Kyo-Hak Publishing Company Limited., 252-259 pp.
- Kim, Y.U., & Han, K.H. (1990). Early life history of the Korean bitterling, *Rhodeus uyekii* (Cyprinidae), reared in the laboratory. *Korean Journal of Ichthyology*, 2(2), 159-168.
- Loewe, H., & Eckmann, R. (1988). The ontogeny of the alimentary tract of Coregonid larvae: normal development. *Journal of Fish Biology*, 33(6), 841-850. <http://dx.doi.org/10.1111/j.1095-8649.1988.tb05531.x>
- Lythgoe, J.N. (1979). The Ecology of Vision. Oxford, UK, Clarendon Press, 1-261 pp.
- O'Connell, C.P. (1976). Histological criteria for diagnosing the starving condition in early post yolk sac larvae of the Northern anchovy, *Engraulis mordax* Girard. *Journal of Experimental Marine Biology and Ecology*, 25(3), 285-312. [http://dx.doi.org/10.1016/0022-0981\(76\)90130-1](http://dx.doi.org/10.1016/0022-0981(76)90130-1)
- Otake, T., Hirokawa, J., Fujimoto, H., & Imaizumi, K. (1995). Fine structure and function of the gut epithelium of pike eel larvae. *Journal of Fish Biology*, 47(1), 126-142. <http://dx.doi.org/10.1006/jfbi.1995.0117>
- Park, I.-S., Im, J.H., & Jang, C.I. (1996). A study on the yolk absorption and early growth in the alevin of rainbow trout, *Oncorhynchus mykiss*. *Korean Journal of Ichthyology*, 8(1), 49-55.
- Park, I.-S., Im, S.Y., Hur, J.W., & Jeong, G.S. (2006a). Early growth and development of eye in dotted gizzard shad, *Konosirus punctatus*. *Development and Reproduction*, 10(2), 93-96.
- Park, I.-S., & Kim, D.S. (2000). Comparison of some tissues in diploid and triploid hybrid between mud loach, *Misgurnus mizolepis* and cyprinid loach, *M. anguillicaudatus*. *Development and Reproduction*, 4(1), 19-28.
- Park, I.-S., Kim, J.M., Kim, Y.H., & Kim, D.S. (1988). Influence of lidocaine as an anaesthetic for marine fishes. *Journal of Fish Pathology*, 1(2), 123-130.
- Park, I.-S., Park, H.J., Gil, H.W., & Goo, I.B. (2012). Early growth and characteristic of histological eye development in post parturition dark banded rockfish, *Sebastes inermis*. *Development and Reproduction*, 16(2), 101-106.
- Park, I.-S., Seol, D.W., Cho, S.H., Song, Y.C., Choi, H.J., Noh, C.H., Myoung, J.G., & Kim, J.M. (2006b). Morphogenesis of the eye of brown croaker (*Miichthys miiuy*). *Ocean and Polar Research*, 28(3), 287-290. <http://dx.doi.org/10.4217/opr.2006.28.3.287>
- Park, K.N., & Kim, C.H. (1990). Egg and larval development and seasonal sex ratio of Korean endemic fresh water fish, *Rhodeus uyekii*. *Journal of Natural Science Research Institute Jeonju University*, 3(1), 29-33.
- Rodriguez, A., & Gisbert, E. (2001). Morphogenesis of the eye of Siberian sturgeon. *Journal of Fish Biology*, 59(5), 1427-1429. <http://dx.doi.org/10.1006/jfbi.2001.1744>
- Strüssmann, C.A., & Takashima, F. (1990). Hepatocyte nuclear size and nutritional condition of starved pejerrey, *Odontesthes bonariensis* (Cuvier et Valenciennes). *Journal of Fish Biology*, 36(1), 59-65. <http://dx.doi.org/10.1111/j.1095-8649.1990.tb03519.x>
- Takashi, H. (1982). An Atlas of Fish Histology. Tokyo, Japan, Kodansha Limited., 147 p.
- Theilacker, G.H. (1978). Effect of starvation on the histological and morphological characteristics of jack mackerel, *Trachurus symmetricus* larvae. *Fishery Bulletin*, 76(2), 403-414.
- Wagner, H.J. (1990). Retinal structure of fishes. In R. Douglas & M. Diamgoz (Eds.), *The Visual System of Fish* (pp. 109-157). London, UK, Chapman and Hall., 526 pp.
- Walls, G.L. (1942). The Vertebrate Eye and Its Adaptive Radiation. Facsimile edition. New York, USA, Hafner Publishing Company., 1-302 pp.
- Zhang, C.I., Sohn, M.H., Seong, K.B., & Park, I.-S. (1995). Yolk absorption and growth of chum salmon, *Oncorhynchus keta* alevin. *Korean Journal of Fishery Aquatic Sciences*, 28(5), 539-548.